

Ukr Neurosurg J. 2024;30(2):14-19
doi: 10.25305/unj.298375

A simple CT-scan-assisted craniotomy for small superficial cortical lesions in rural conditions

Alexandrina Nikova^{1,2,3}, Efthymia Theodoropoulou¹, Theodossios A. Birbilis¹

¹ Department of Neurosurgery, Democritus University of Thrace Medical School, University Hospital of Alexandroupolis, Alexandroupolis, Greece

² Department of Neurosurgery, Asclipieio Voulas, General Hospital, Athens, Greece

³ Department of Neurosurgery, "Aghia Sophia" Childrens' hospital, Athens, Greece

Received: 12 February 2024

Accepted: 05 April 2024

Address for correspondence:

Alexandrina S. Nikova, Department of Neurosurgery, University Hospital of Alexandroupolis, GR- 68100, Dragana, Alexandroupolis, Greece, e-mail: nikovaalex@gmail.com

Objective: Despite the excellence and modernization in medicine and neurosurgery, many countries, including Greece, still lack neuronavigational techniques, or hospital budget to cover the neuronavigation expenses. Therefore, help in the craniotomy design is needed, not only to safely remove a superficial lesion but also to help cut the expenses of neuronavigation in cases of economic challenges. The current study aims to present a new simple technique for craniotomy design for superficial cortical lesions.

Materials and methods: The technique was applied as an urgent lifesaving method because of lacking frameless neuronavigation to 35 patients (19 males and 16 females) with superficial cortical lesions during a five-year period. This technique requires computer tomography (CT) scan, needle, and methylene blue dye. The patients were operated on at the neurosurgical department of Democritus University Hospital in Alexandroupolis, Greece.

Results: From those 35 individuals, 16 had brain metastases, six patients had meningioma, six patients had glioma tumor, two had an abscess, two patients had arteriovenous malformation (AVM) and three patients had brain hematoma. The lesion was completely resected in all the 35 patients without any complications from the craniotomy or the colorant dye infusion. The accuracy of the technique compared with the frameless neuronavigation of the literature was extremely high.

Conclusion: This is a simple and cheap technique for craniotomy design in case of superficial cortical lesions. It could be used in rural conditions or in hospitals with limited resources, as long as there is a computed tomography scan, craniotomy device and a dye stain.

Keywords: craniotomy; CT scan; rural conditions; design; superficial cortical lesion

Introduction

Incision and craniotomy planning are crucial components in the field of neurosurgery. The primary target of the optimal craniotomy is to protect the underlying structures and anatomy while permitting the most optimal exposure of the lesion [1]. The lesion is the primary navigation to the used approach.

During the last few years, there has been a rapid development of technological aids designed to solve the issues as mentioned above. The following guidance techniques are indicatively referred to as neuronavigation. These techniques, which are currently available and provide very high accuracy, are still too expensive to obtain. Worldwide, numerous hospitals lack the equipment that would enable them to use the advantage gained from the implementation of these techniques.

The current study aims to present a new technique for the design of craniotomy for superficial lesions in rural conditions and the authors' experience with the utilization of this simple and easily applicable method.

Material and Methods

Surgical Technique

In order to identify cortical lesions, and thus, design a craniotomy, the author (T.B.) has developed the following simple technique. Each patient has a written consent for the performance of the technique, as well as for his personal data usage.

The leading indicator for the utilization of the technique is the detection of a small (<5cm) superficial lesion so that the precise design of the craniotomy could be achieved.

The requirements for employing the technique are simple and inexpensive materials, in a specific methylene blue solution, a needle and an insulin syringe. It is also required that the hospital has a computer tomography (CT) scanner and a craniotomy device.

The patient undergoes a CT scan of the brain initially. While he is lying in the scanner, we choose the image showing the largest diameter of the lesion. Then, the technician/ operator opens the laser of the machine, thus pointing it out to the location of the lesion on the skull.

Copyright © 2024 Alexandrina Nikova, Efthymia Theodoropoulou, Theodossios A. Birbilis



This work is licensed under a Creative Commons Attribution 4.0 International License
<https://creativecommons.org/licenses/by/4.0/>

After that, the physician sterilizes the skull area and inserts a small needle of insulin in the theoretical centre of the lesion (or the location that he believes is the centre of the lesion). The needle remains pinned subcutaneously on the skull.

A second CT- scan is obtained with the needle wedged in the skin (theoretically in the centre of the lesion).

The physician repositions the needle if it is not in the centre so that it is located precisely in the centre of the lesion and obtains a repeated CT scan to ensure that it is.

When the surgeon is confident for the location of the needle, he marks its position on the skin (**Figure 1**).

After that, a tiny amount of methylene blue (0.5–1cc) is injected into the galea aponeurotica.

On the next day, the patient is taken into the operating room. We make the incision according to our mark at the most optimal location for lesion exposure and postoperative restoration process, trying to position it in the centre. After the skin flap has been restored, the surgeon detects the exact point of stained with methylene blue of the galea aponeurotica. This point is

where the first keyhole is made. Thereafter, the drilling is made in a circle-wise way, so that the keyhole can remain in the centre (**Figure 2**).

Data Collection and Selection

This method was adopted in the department of neurosurgery at the University Hospital of Alexandroupolis for a period of five years (2005-2010). The patients were operated on as isolated cases in urgent need of navigation but lacking hospital resources. Each patient was informed for the procedure and possible complications and signed a written consent form. For the present study, the authors retrospectively collected the data from those cases.

The inclusion criteria included superficial lesions <5cm.

The technique was applied in 35 brain surgeries, involving 19 males and 16 females with an average age of 56.5 years. From those 35 individuals, 16 had brain metastases, 6 – meningioma, 6 – glioma tumor, 2 – abscesses, 2 – arteriovenous malformation (AVM) and 3 – brain hematoma.

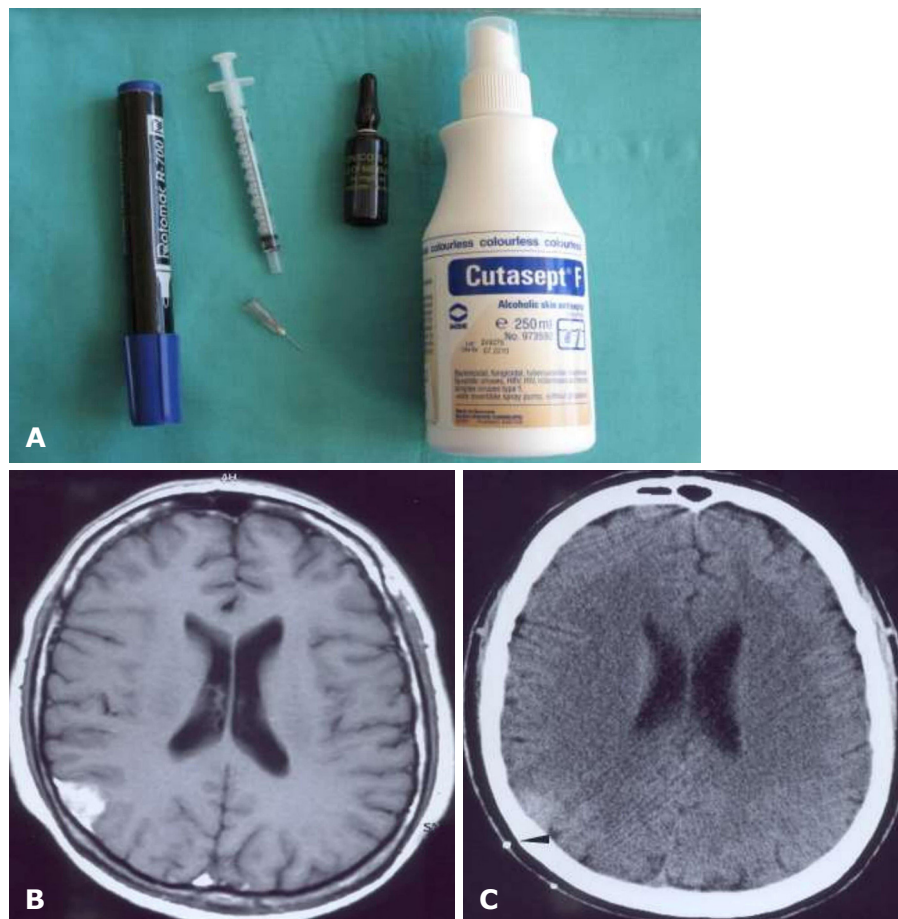


Figure 1. Preoperative craniotomy design. A - needed tools; B - CT scan showing the largest diameter of the lesion; C - CT scan with pinned needle.

This article contains some figures that are displayed in color online but in black and white in the print edition.

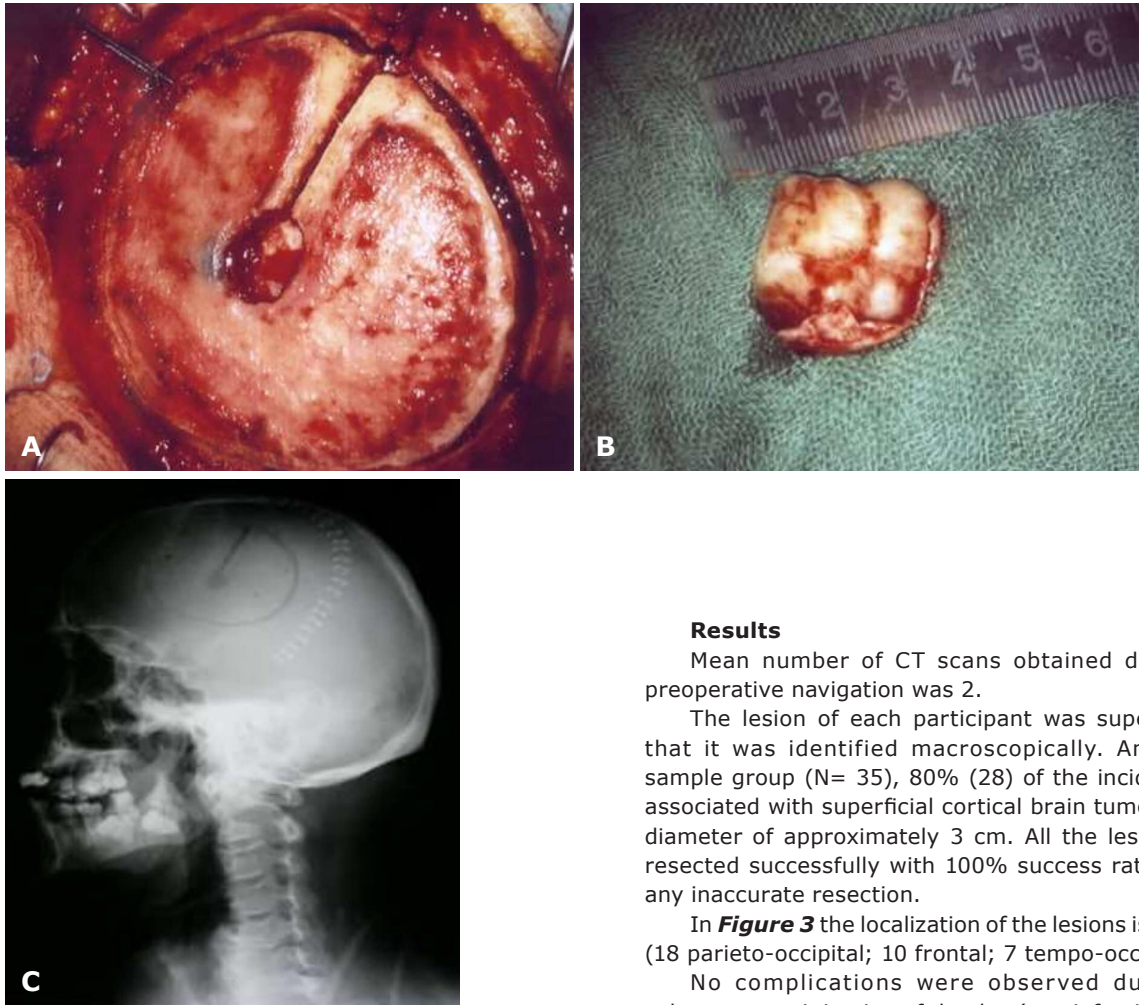


Figure 2. Surgical performance of the technique. A - Craniotomy performance; B - resected lesion; C - Postoperative x-ray

Results

Mean number of CT scans obtained during the preoperative navigation was 2.

The lesion of each participant was superficial so that it was identified macroscopically. Among the sample group (N= 35), 80% (28) of the incidents was associated with superficial cortical brain tumors with a diameter of approximately 3 cm. All the lesions were resected successfully with 100% success rate without any inaccurate resection.

In **Figure 3** the localization of the lesions is depicted (18 parieto-occipital; 10 frontal; 7 tempo-occipital).

No complications were observed due to the subcutaneous injection of the dye (e.g. infection) or the craniotomy. The patients were lost for follow-up.

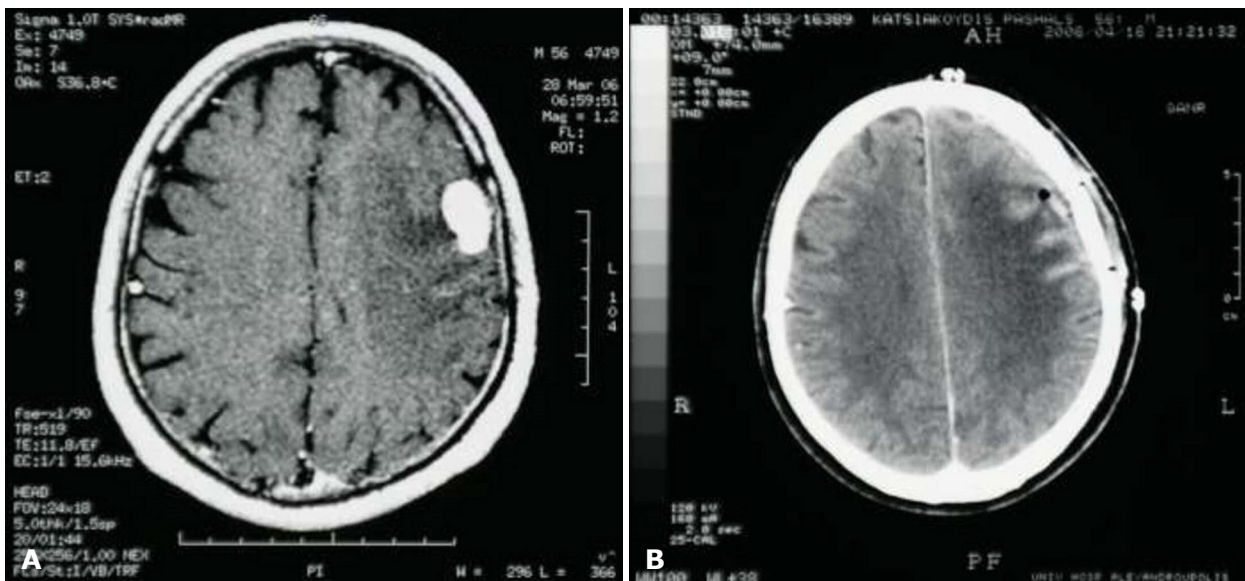


Figure 3. Results. A - Preoperative CT showing the lesion; B - Postoperative CT showing its resection.

Discussion

Craniotomy is one of the most ancient procedures dating up to the Mayan [2]. The craniotomy as procedure, however, was structured for the first time by Hippocrates, who succeeded to review and constitute practice recommendations [3]. Despite of the wide use of craniotomy for the variety of skull injuries, it was not long ago when the craniotomy was first used for the removal of cortical lesion [3, 4].

The resection of the lesion was based on preoperative images, surgeon's imagination and good knowledge of anatomy [5]. Craniotomies and surgical orientations were applied based on the preoperative images and anatomical landmarks. This was changed with the introduction of neuronavigation systems and stereotaxy. The surgical practice thereafter was easier and safer for the patients.

Currently, patient's positioning and craniotomy design are fundamental for the neurosurgical practice of lesion resection. Patient's positioning is also the fundamental part of the neuroanesthesiology. The most favorable head position is the one providing maximal exposure of the lesion at the shortest distance; and if possible, positioned in a way that the craniotomy would be parallel to the ground [6].

According to Clatterbuck et al. [7] there are five classical types of craniotomy approaches: frontal, temporal, parietal, occipital and one to the posterior fossa and six, according to the modern neurosurgery: anterior and posterior parasagittal, pterional, subtemporal, midline and lateral suboccipital. As mentioned earlier, the lesion defines the used approach.

The nowadays known methylene blue dye was initiated by Caro et.al. in the XIX century by replacing the p-phenylenediamine with N, N-dimethyl-p-phenylenediamine [8, 9, 10]. Until now, the methylene blue is known with about 222 other names [10].

Its medical application began early with Paul Ehrlich in 1880 year, who discovered the staining properties of the methylene blue [11]. A few years later, Bondoni et.al. [12] found the "calming" opportunities of the dye without sharing very detailed information on the subject.

Currently, methylene blue is used mainly to treat methemoglobinemia, vasoplegic adrenaline-resistant shock, Alzheimer's disease, pediatric malaria, priapism and to prevent urinary tract infections in advanced-age patients [10]. Moreover, it is widely used to do lymphatic mapping in cancer patients [13]. Long before that, it has been reported that MB injection could be used in attempt to find an arteriovenous malformation (AVM) in the intestines. Such study was reported by Fogler et.al. [14], where methylene blue injection was used as an intraoperative guide for the resection of AVMs in the small intestine. After this discovery, Gifford et.al. [15] used MB for mapping of the enteric hemorrhage. Similarly, Liu et al. [16] used MB to find the exact structure of a brain AVM.

Other applications include experimental works with animals and plants [10].

After the approval of the methylene blue or PROVAYBLUE® by the Food and Drug Administration (FDA), the latter approved other three dyes, based on the methylene blue formula: Evans Blue, Patent Blue and Trypan Blue [17]. Evans Blue was withdrawn for

safety reasons, Trypan Blue (VisionBlue®) is used in ophthalmology and Patent Blue appeared to be the same as the methylene blue in lymphatic cancer mapping [18, 19].

Methylene blue is a dye, used for years in neurosurgery. Initially it was utilized to detect cerebrospinal fluid blockage and leakage [20, 21, 22]. Later, because of its indisputable help in cancer detection, it was used for the detection of glioma [23]. Others, such as Phelan and colleagues [24] used the methylene blue intraoperatively to detect the intracranial extent of the dermoid cysts, thus avoiding unnecessary craniotomy.

Watts et al. [25] tested the methylene blue dye in rats with mild traumatic brain injury (TBI). According to his study, the rats injected with the dye had smaller lesions. Moreover, Shen et.al. [26] found that MB had a protective role *in vivo* and *in vitro* for the blood-brain barrier and reduced the rate of apoptosis after TBI.

In a triple-blind randomized placebo-controlled study, Farrokhi et al. [27] found that methylene blue improves the postoperative low back pain, as well as the quality of life.

Lee et.al. [28] in a novel study found that MB has cytotoxic action in neuroblastoma and astrocytoma cells, thus, inhibiting the action of guanylyl cyclase. The latter is an enzyme that transforms guanosine triphosphate (GTP) to cyclic guanosine monophosphate (cGMP) and pyrophosphate.

Finally, Snuderl et al. [29] presented the use of MB in the field of perioperative neuro-oncology. In his attempt to achieve better intraoperative diagnosis, he took tissue samples from the tumors and "normal tissue" which should be resected and injected them with methylene blue. After a few minutes the samples were image recorded on the microscope. The images were similar to the ones obtained with a typical histopathological staining with eosin and hematoxylin.

However, to our knowledge, no study has reported its use for craniotomy design to date.

Nevertheless, this method cannot be applied to deep lesions, as no visual contact is feasible in this case. Furthermore, the size of lesions should not be smaller than 5 cm, because in that case the accuracy of the method could not be maintained at the desired level, due to the possible displacement of the skin (during the placement of the head in Mayfield).

Neuronavigation

The need of anatomical localization started gaining importance with the progress of understanding of spatial organization [30, 31]. The progress of imaging such as CT and magnetic resonance imaging (MRI) enhanced the knowledge of anatomical localization and the need for neuronavigation. Leksell [32] and Spiegel [33] improved further the precision of neurosurgery with the frame-based navigation, until the frameless neuronavigation system emerged. The latter combines data from variety of modalities (MRI, functional MRI, diffusion tensor imaging (DTI), CT) reorganizing it into 3Dimensional (3D) images, in order to target a lesion located in any area within the nervous system. [31]

The frameless navigation systems are believed to be accurate as much as the frame-based navigation systems, targeting accuracy intraoperatively in the

range of two-three mm [34]. The mistakes of the frameless stereotactic navigation system either from the preoperative technique of probe tracking, or from the preoperative images (too old images or low quality) and their registration to the frameless navigation system.

As mentioned previously, the present technique had a quite high accuracy taking into consideration the fact that it was CT-guided infusion of MB. The images were taken a few hours before surgery and the surgeon, as well as the radiologist were present at the moment of their performance.

To our knowledge, this is the first study in the literature to present the use of MB as a cheap tool for neuronavigation. Even though technology and resources for healthcare are improving, many hospitals lack neuronavigation and resources. Therefore, the physicians should be able to still perform at their best despite the present challenges. Despite of its novelty, the study has a few limitations. The patients were enrolled during a long period of time and no follow up was available. The hospital covers a large area of the North – East Greece and many of the patients were lost due to their localization. Finally, the study sample was too heterogenous and insufficient to obtain any comparison for navigation accuracy.

Conclusion

The present technique is effortless and cheap, with sufficiently good precision for specific lesions. Therefore, the authors would like to introduce the above-described technique as it is a safe, easy and affordable method which can be widely used in hospitals that do not have the potential of using neuronavigation.

Disclosure

Conflict of interest

No conflict of interest to declare.

Ethical approval

The method and research were approved by the hospital's ethical committee.

Informed consent

Each patient provided a written consent for the performance of the technique, as well as for the use of his/her personal data.

Funding

No funding received.

References

1. Cranial approaches. General principles [Internet]. Neurosurgical atlas; 2024. <https://www.neurosurgicalatlas.com/volumes/cranial-approaches/general-principles>
2. Nikova A, Birbilis T. The Basic Steps of Evolution of Brain Surgery. *Maedica (Bucur)*. 2017 Dec;12(4):297-305.
3. Sperati G. Craniotomy through the ages. *Acta Otorhinolaryngol Ital*. 2007 Jun;27(3):151-6/
4. Kirkpatrick DB. The first primary brain-tumor operation. *J Neurosurg*. 1984 Nov;61(5):809-13. doi: 10.3171/jns.1984.61.5.0809
5. Thomas NWD, Sinclair J. Image-Guided Neurosurgery: History and Current Clinical Applications. *J Med Imaging Radiat Sci*. 2015 Sep;46(3):331-342. doi: 10.1016/j.jmir.2015.06.003
6. Rozet I, Vavilala MS. Risks and benefits of patient positioning during neurosurgical care. *Anesthesiol Clin*. 2007 Sep;25(3):631-53, x. doi: 10.1016/j.anclin.2007.05.009
7. Clatterbuck R, Tamargo R: Surgical Positioning and Exposures for Cranial Procedures. In: Winn H, editor. *Youmans Neurological Surgery*. 5 ed. Philadelphia, Pennsylvania: Saunders Elsevier Inc, 2004: 623–645.
8. Caro H. Improvement in the production of dyestuffs from methyl-aniline. US patent 204796, 1878.
9. Caro H. Verfahren zur Darstellung blauer Farbstoffe aus Dimethylanilin und anderen tertiären aromatischen Monoaminen. German patent 1886 (December 15, 1877); British patent 3751 (October 9, 1877), 1877.
10. Cooksey CJ. Quirks of dye nomenclature. 8. Methylene blue, azure and violet. *Biotech Histochem*. 2017;92(5):347-356. doi: 10.1080/10520295.2017.1315775
11. Ehrlich P: Methodologische Beiträge zur Physiologie und Pathologie der verschiedenen Formen der Leukocyten. *Z Klin Med*. 1880;1:553–560. <https://www.pei.de/SharedDocs/Downloads/DE/institut/veroeffentlichungen-von-paul-ehrlich/1877-1885/1880-methodologisch-beitraege-physiologie-pathologie.pdf>
12. Bodoni P. Dell'azione sedativa del bleu di metilene in varie forme di psicosi. *Clin Med Ital*. 1899;24:217–222.
13. Margetis K, Rajappa P, Tsiouris AJ, Greenfield JP, Schwartz TH. Intraoperative stereotactic injection of Indigo Carmine dye to mark ill-defined tumor margins: a prospective phase I-II study. *J Neurosurg*. 2015 Jan;122(1):40-8. doi: 10.3171/2014.9.JNS14113
14. Fogler R, Golembe E. Methylene blue injection. An intraoperative guide in small bowel resection for arteriovenous malformation. *Arch Surg*. 1978 Feb;113(2):194-5. doi: 10.1001/archsurg.1978.01370140084017
15. Gifford SM, Peck MA, Reyes AM, Lundy JB. Methylene blue enteric mapping for intraoperative localization in obscure small bowel hemorrhage: report of a new technique and literature review: combined intraoperative methylene blue mapping and enterectomy. *J Gastrointest Surg*. 2012 Nov;16(11):2177-81. doi: 10.1007/s11605-012-1964-9
16. Liu P, Zhang H, Qiu T, Zhu W. Trans-radial artery microcatheter angiography-assisted juvenile ruptured brainstem arteriovenous malformation resection. *Acta Neurochir (Wien)*. 2024 Jan 30;166(1):53. doi: 10.1007/s00701-024-05915-4
17. PROVAYBLUE (methylene blue) injection. Highlights of prescribing information [Internet]. U.S. Food and Drug Administration; 2017. https://www.accessdata.fda.gov/drugsatfda_docs/label/2017/204630s005lbl.pdf
18. Pharmacology reviews: Application number :21-670 [Internet]. Centre for drug evaluation and research; 2004. https://www.accessdata.fda.gov/drugsatfda_docs/nda/2004/21-670_VisionBlue_Pharmr.PDF
19. Evans blue [Internet]. U.S. Food and Drug Administration; 2022. <https://www.accessdata.fda.gov/scripts/cder/daf/index.cfm?event=overview.process&AppNo=008041>
20. Evans JP. Warning against intrathecal use of methylene blue. *Journal of the American Medical Association*. 1959 Jan 31;169(5):526. doi:10.1001/jama.1959.03000220106025
21. Sharr MM, Weller RO, Brice JG. Spinal cord necrosis after intrathecal injection of methylene blue. *J Neurol Neurosurg Psychiatry*. 1978 Apr;41(4):384-6. doi: 10.1136/jnnp.41.4.384
22. ECKER A. Cerebrospinal rhinorrhea by way of the eustachian tube; report of cases with the dural defects in the middle or posterior fossa. *J Neurosurg*. 1947 Mar;4(2):177. doi: 10.3171/jns.1947.4.2.0177
23. Wirth D, Snuderl M, Curry W, Yaroslavsky A. Comparative evaluation of methylene blue and demeclocycline for enhancing optical contrast of gliomas in optical images. *J Biomed Opt*. 2014 Sep;19(9):09504. doi: 10.1117/1.JBO.19.9.09504
24. Phelan AL, Jones CM, Ceschini AS, Henry CR, Mackay DR, Samson TD. Sparing a Craniotomy: The Role of Intraoperative Methylene Blue in Management of Midline Dermoid Cysts. *Plast Reconstr Surg*. 2017 Jun;139(6):1445-1451. doi: 10.1097/PRS.0000000000003369
25. Talley Watts L, Long JA, Chemello J, Van Koughnet S, Fernandez A, Huang S, Shen Q, Duong TQ. Methylene blue is neuroprotective against mild traumatic brain injury. *J Neurotrauma*. 2014 Jun 1;31(11):1063-71. doi: 10.1089/neu.2013.3193
26. Shen J, Xin W, Li Q, Gao Y, Yuan L, Zhang J. Methylene Blue Reduces Neuronal Apoptosis and Improves Blood-

- Brain Barrier Integrity After Traumatic Brain Injury. *Front Neurol.* 2019 Nov 8;10:1133. doi: 10.3389/fneur.2019.01133
27. Farrokhi MR, Lotfi M, Masoudi MS, Gholami M. Effects of methylene blue on postoperative low-back pain and functional outcomes after lumbar open discectomy: a triple-blind, randomized placebo-controlled trial. *J Neurosurg Spine.* 2016 Jan;24(1):7-15. doi: 10.3171/2015.3.SPINE141172
28. Lee YS, Wurster RD. Methylene blue induces cytotoxicity in human brain tumor cells. *Cancer Lett.* 1995 Jan 27;88(2):141-5. doi: 10.1016/0304-3835(94)03629-w
29. Snuderl M, Wirth D, Sheth SA, Bourne SK, Kwon CS, Ancukiewicz M, Curry WT, Frosch MP, Yaroslavsky AN. Dye-enhanced multimodal confocal imaging as a novel approach to intraoperative diagnosis of brain tumors. *Brain Pathol.* 2013 Jan;23(1):73-81. doi: 10.1111/j.1750-3639.2012.00626.x
30. Risholm P, Golby AJ, Wells W 3rd. Multimodal image registration for preoperative planning and image-guided neurosurgical procedures. *Neurosurg Clin N Am.* 2011 Apr;22(2):197-206, viii. doi: 10.1016/j.nec.2010.12.001
31. Orringer DA, Golby A, Jolesz F. Neuronavigation in the surgical management of brain tumors: current and future trends. *Expert Rev Med Devices.* 2012 Sep;9(5):491-500. doi: 10.1586/erd.12.42
32. Leksell L. The stereotaxic method and radiosurgery of the brain. *Acta Chir Scand.* 1951 Dec 13;102(4):316-9
33. Spiegel EA, Wycis HT, Marks M, Lee AJ. Stereotaxic Apparatus for Operations on the Human Brain. *Science.* 1947 Oct 10;106(2754):349-50. doi: 10.1126/science.106.2754.349
34. Mascott CR. In vivo accuracy of image guidance performed using optical tracking and optimized registration. *J Neurosurg.* 2006 Oct;105(4):561-7. doi: 10.3171/jns.2006.105.4.561