

Ukr Neurosurg J. 2022;28(4):19-25  
doi: 10.25305/unj.260102

## Tumors of the lateral and third ventricles of the brain. Possibilities of endoscopic transventricular surgery. Prospects and prognosis

Orest I. Palamar, Andriy P. Huk, Dmytro S. Teslenko, Dmytro I. Okonskyi, Oleksandr S. Usatov

Department of Endoscopic and Craniofacial Neurosurgery with a Group of Adjuvant Treatment, Romodanov Neurosurgery Institute, Kyiv, Ukraine

Received: 28 June 2022  
Accepted: 28 October 2022

### Address for correspondence:

Orest I. Palamar, Department of Endoscopic and Craniofacial Neurosurgery with a Group of Adjuvant Treatment, Romodanov Neurosurgery Institute, 32 Platona Mayborody st., Kyiv, Ukraine, 04050, e-mail: p\_orest@ukr.net

Tumors of the lateral and third ventricles of the brain are uncommon in the general population. Taking into account possible disability, expected duration and quality of life of the patient in the postoperative period, radical removal of these tumors, especially invasive ones, are debatable.

**Purpose:** to determine the possibilities of endoscopic transventricular surgery for tumors of the lateral and third ventricles of the brain.

**Materials and methods.** Between 2015 and 2021, 61 patients with lateral and third ventricle tumors were treated, 9 of which were primary and 52 were invasive.

All patients had a preoperative Karnofsky Performance scale score  $\geq 70$  points. Preoperative neurological status: non-focal neurological symptoms were observed in all patients, central significant hemiparesis (up to 2 points) - in 5, cognitive-mnemonic disorders - in 31, opto-chiasmatic syndrome - in 2. Obstructive hydrocephalus was diagnosed in all patients. All patients underwent full-endoscopic removal by frontal transcortical transventricular approach.

**Results.** Total tumor resection (within healthy tissues) was performed in 34 patients, subtotal (up to 90%) - in 17, partial - in 10 patients. The postoperative condition according to Karnofsky Performance scale in all patients was  $\geq 70$  points. Hemiplegia was registered in 8 (13.1%) patients (sustained deficiency, hemiparesis (up to 3 points) - in 2 (1.22%) patients), hemianopsia - in 4 (6.5%) patients, short-term memory impairment - in 9 (14.75%), regression was observed 2-4 weeks after surgery. Thirty-seven (60.7%) patients died. The remaining patients (39.3%) are under observation. Median survival was 33 weeks (95% confidence interval (CI) 28-40 weeks). Postoperative survival in patients with glioblastoma was 15 weeks, median survival was 9.5 weeks (95% CI, 4-15 weeks). Of the patients with anaplastic astrocytoma, 13 (92.9%) patients died within 38 weeks after surgery, the median survival was 18 weeks (95% CI, 14.5-29.0 weeks), 1 (7.1%) patient was under observation. Patients with anaplastic oligodendroglioma had a median survival of 34.5 weeks (95% CI - 28-40 weeks), 15 (65.2%) patients died within 40 weeks, 8 (34.8%) patients are under observation. The difference between groups in survival was statistically significant ( $p < 0.0001$ ). Median survival in women was 34.5 weeks (95% CI, 29-40 weeks), in men, 28 weeks (95% CI, 18-39 weeks). There were 12 (42.9%) women and 12 (36.4%) men who survived for more than 60 weeks. No statistically significant difference was found between male and female survival rates ( $p = 0.309$ ).

**Conclusions.** The ability of achieving the optimal resection volume of primary and invasive tumors of the third and lateral ventricles allows recommending the anterior endoscopic transcortical transventricular approach as an effective method of surgical treatment of these tumors. Radical endoscopic resection, as the first stage of combined treatment of patients with malignant tumors of the third and lateral ventricles, increases the patients' life expectancy with a minimal risk of postoperative neurological complications, comparable to the life expectancy of patients with malignant tumors of supratentorial localization. To eliminate obstructive hydrocephalus and prevent the obstruction of CSF circulation in case of postoperative edema or continued growth in invasive tumors of the lateral and third ventricles, it is advisable to perform triventriculocisternostomy.

**Key words:** lateral ventricle; third ventricle; endoscopic approach; transcortical approach; transforaminal approach; transchoroidal approach; primary tumors; invasive tumors



## Introduction

Tumors of the lateral and third ventricles of the brain are rare in the general population [1, 2]. The radicality of their removal, especially invasive tumors, is debatable [3–6], given possible disability [2, 3, 6–8], expected duration and quality of life of the patient in the postoperative period [1, 3, 4, 9]. Surgery for invasive tumors of the ventricular system mainly consists in their biopsy [2], which is due to their primary growth zone from functionally important brain areas (thalamus, basal ganglia, etc.) [2–6, 7, 8, 10]. The development and implementation of endoscopic minimally invasive techniques of surgical treatment of tumors of the ventricular system of the brain can reduce the formation of new postoperative neurological deficits and prolong the life expectancy of patients.

**Purpose:** to determine the possibilities of endoscopic transventricular surgery for tumors of the lateral and third ventricles of the brain.

## Materials and methods

### Study participants

Between 2015 and 2021, 61 patients with lateral and third ventricle tumors were treated, 9 of which were primary and 52 were invasive.

Informed and voluntary written consent to participate in the study was obtained from all patients.

The study was approved by the Committee on Ethics and Bioethics of the Institute of Neurosurgery named after Acad. A. P. Romodanov, Ukraine (Minutes № 2 dated April 14, 2021).

### Inclusion criteria:

- 1) age of the patients –  $\geq 18$  years;
- 2) the presence of primary and invasive tumors of the lateral and third ventricles.

### Characteristics of groups

The patients included 33 (54.1%) men and 28 (45.9%) women. The age of patients ranged from 19 to 69 years, with a mean age of  $(43.14 \pm 13.0)$  years.

Primary tumors were diagnosed in 2 men and 7 women, and invasive ones in 31 and 21 patients, respectively.

### Study design

Magnetic resonance imaging (MRI) (T1, T1Gd+, T2, FLAIR) and multispiral computed tomography (including contrast) of the brain were used for preoperative and postoperative assessment.

The Karnofsky Performance Status Scale was used to assess the general clinical status of the patient. In the preoperative period, all patients had  $\geq 70$  points.

A standard neurological examination was performed to assess the neurological status of the patients. Cognitive-mnemonic functions were objectified using the MoCA scale (Montreal Cognitive Assessment-test).

### Preoperative neurological status:

- non-focal neurological symptoms were observed in all patients;
- motor disorders: central significant hemiparesis (up to 2 points) - in 5 patients, others - without motor disorders;
- cognitive-mnemonic disorders - in 31 patients (from 18 to 24/30 points on the MoCA scale);
- opto-chiasmatic syndrome - in 2 patients.

Obstructive hydrocephalus was diagnosed in all patients.

All patients underwent full-endoscopic removal by frontal transcortical (right-sided - 95% of interventions, left-sided - 5% of interventions) transventricular approach in combination with transforaminal (through f. Monro) and anterior transchoroidal (dissection of the anterior parts of the vascular plexus of the lateral ventricle with insufficient dimensions of the interventricular foramen) approach in tumors to the third ventricle (**Fig. 1**). In 11 cases with tumors of the third ventricle, triventriculocisternostomy was additionally performed.

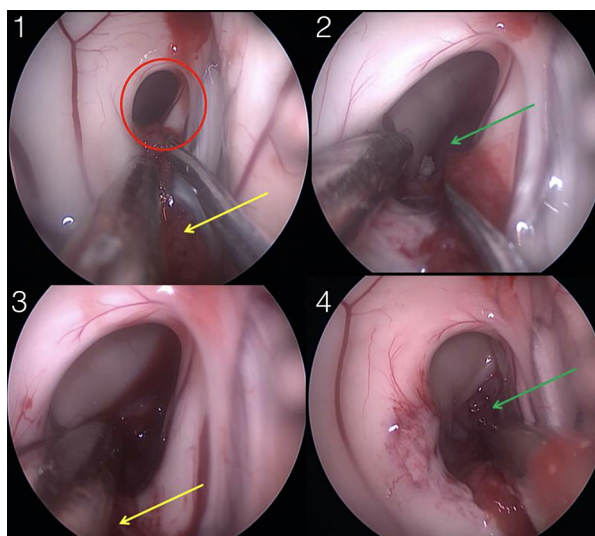
### Statistical analysis

Statistical processing of data was performed using Statistica 10.0 StatSoft Inc. (USA) statistical software package. All accumulated material is standardized, added into the database and subjected to statistical processing using methods of descriptive and non-parametric statistics. Survival analysis was performed using the Kaplan-Meier method. Pearson's chi-squared test was used to determine the difference between the survival of patients in different groups. When comparing survival in different groups, the risk ratio with 95% confidence interval (CI) was used. The results were considered statistically significant provided that the statistical significance level ( $p$ ) was  $< 0.05$ .

## Results and discussion

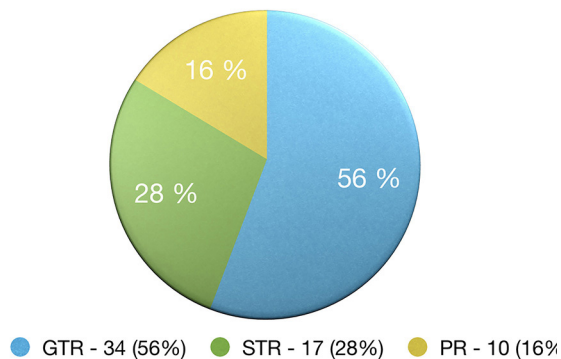
Radical removal of tumors of the lateral and third ventricles of the brain (61 patients): total tumor removal within healthy tissues (gross total resection (GTR)) - in 34 patients, subtotal (up to 90%) tumor removal (subtotal resection (STR)) - in 17, partial removal (PR) - in 10 (**Fig. 2**).

Partial removal of the tumor was associated with significant bleeding. Triventriculocisternostomy was performed in 11 cases.



**Fig. 1.** Gradual expansion of the interventricular foramen by dissection of the anterior parts of the choroid plexus: the red circle shows the interventricular foramen; the yellow arrow indicates the choroid plexus; the green arrow indicates an invasive tumor of the third ventricle

This article contains some figures that are displayed in color online but in black and white in the print edition



**Fig. 2.** Radical resection of tumors of the lateral and third ventricles of the brain (61 patients)

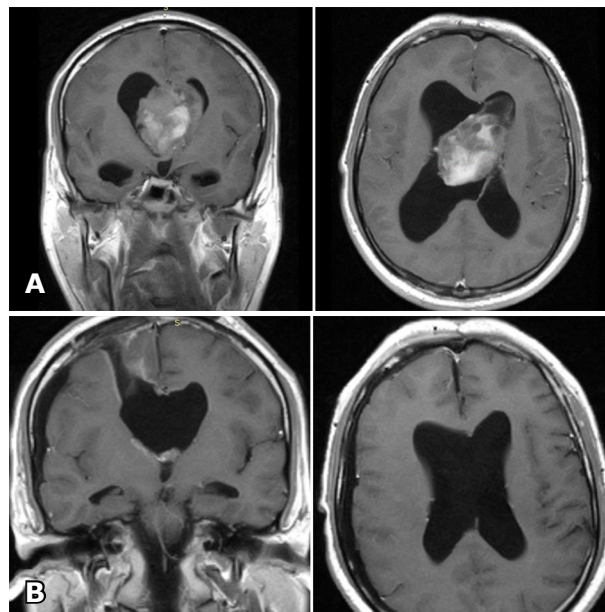
Histological distribution (**Tables 1 and 2**): anaplastic ependymoma – 2 cases (WHO grade 3), central neurocytoma – 6 (WHO grade 2), meningioma – 2 (psammomatous – 1, mixed structure, WHO grade 1), mature teratoma – 1 (WHO grade 1), low grade gliomas (WHO grade 2) – pilomyxoid astrocytoma, fibrillary astrocytoma) – 7, pineoblastoma – 1 (WHO grade 4), high grade gliomas (WHO grade 3-4 – anaplastic oligodendroglioma (**Fig. 3**), anaplastic astrocytoma (**Fig. 4**), anaplastic oligoastrocytoma (**Fig. 5**), glioblastoma) – 42. The maximum tumor size is 6.2 cm.

**Table 1.** Histological distribution of primary tumors of the lateral and third ventricles of the brain

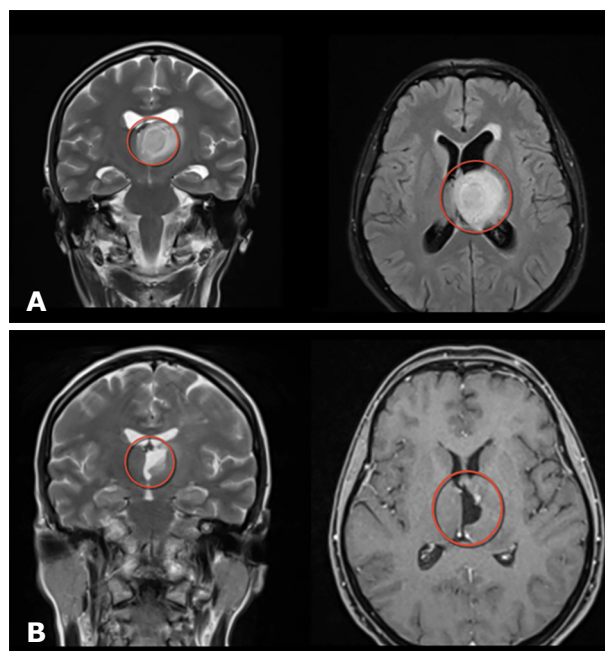
Histologic diagnosis	Abs.	%
Central neurocytoma	6	66,6
Anaplastic ependyma	2	22,23
Mature teratoma	1	11,17

**Table 2.** Histological distribution of invasive tumors of the lateral and third ventricles of the brain

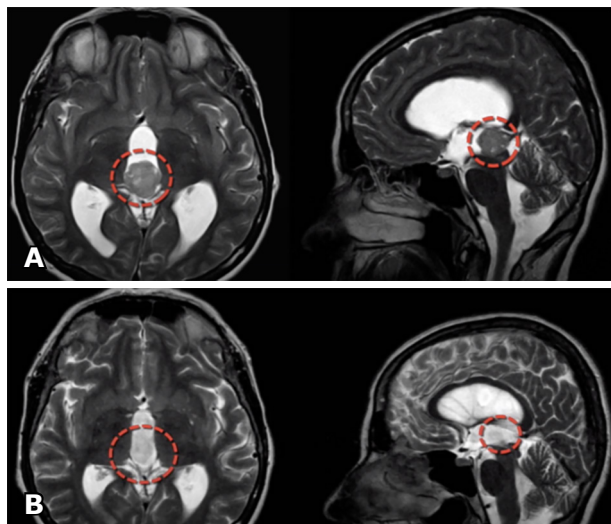
Histologic diagnosis	Abs.	%
Meningioma:	2	3,8
- psammomatous	1	
- mixed structure	1	
Low-grade gliomas:	7	13,6
- pilomyxoid astrocytoma	3	
- fibrillary astrocytoma	4	
High-grade gliomas:	42	80,7
- anaplastic oligodendroglioma	23	44,2
- anaplastic astrocytoma	14	26,9
- glioblastoma	5	9,6
Pineoblastoma	1	1,9



**Fig. 3.** MRI of the brain with intravenous contrast before surgery (A) and 3 months after surgery (B). Total removal of the tumor of the lateral ventricles with invasion into the third ventricle through f. Monro (HPR – anaplastic oligodendroglioma, Gr III)



**Fig. 4.** MRI of the brain before surgery (A) and 3 months after surgery (B). Total removal of the tumor of the left thalamus (HPR – anaplastic astrocytoma, Gr III). Hydrocephalus regressed in the postoperative period



**Fig. 5.** MRI of the brain before surgery (A) and 3 months after surgery (B). Total removal of an invasive tumor into the posterior parts of the third ventricle (HPR - anaplastic oligoastrocytoma, Gr III). Hydrocephalus regressed in the postoperative period

The postoperative condition of all patients was assessed as  $\geq 70$  points on the Karnofsky scale. Neurological complications were recorded: hemiplegia in 8 (13.1%) patients (sustained deficiency, appearance of hemiparesis (muscle strength up to 3 out of 5 points) in 2 (1.22%), increase in muscle strength up to 4-5 points within 3 weeks after surgery), the occurrence of hemianopsia - in 4 (6.5%), transient mutism - in 6 (9.8%), which regressed within 1-3 weeks after surgery, short-term memory impairment - in 9 (14.75%), which regressed 2-4 weeks after surgery.

There is no postoperative mortality.

The regression of general brain symptoms was observed in all patients, in 74% - improvement of the cognitive-mnemonic sphere in comparison with the preoperative level within 1-2 weeks after surgery.

All patients with malignant tumors received radiation and chemotherapy after surgical treatment (taking into account individual sensitivity) according to standardized protocols.

Thirty-seven (60.7%) out of 61 patients who underwent surgery died, the rest were under observation. Median survival was 33 weeks (95% CI - 28-40 weeks) (**Fig. 6**).

There were 42 patients with anaplastic astrocytoma, oligodendroglioma, and glioblastoma. During the follow-up period, 33 (78.6%) patients died. Postoperative survival of patients was 39 weeks, median survival was 28 weeks (95% CI - 21.5-34.5 weeks). Nine (21.4%) patients were under observation (**Fig. 7**).

During the follow-up period, 78.6% of patients with anaplastic astrocytoma, oligodendroglioma, and glioblastoma died, whereas 21.4% died among patients with other, less malignant tumors (**Table 3**). Postoperative survival in patients with glioblastoma was 15 weeks, median survival was 9.5 weeks (95% CI - 4-15 weeks). Among patients with anaplastic astrocytoma, 13 (92.9%) died within 38 weeks after surgery, median survival was 18 weeks (95% CI - 14.5-29 weeks), 1 (7.1%) patient was under observation. The median survival in patients

with anaplastic oligodendroglioma was 34.5 weeks (95% CI - 28-40 weeks), 15 (65.2%) of them died within 40 weeks, 8 (34.8%) were under observation (**Fig. 8**). The difference between the groups in terms of survival was statistically significant ( $p < 0.0001$ ).

The risk of death from glioblastoma is 5.4 times higher than from anaplastic astrocytoma, and 13.8 times higher than from anaplastic oligodendroglioma. The lowest risk of death was from anaplastic oligodendroglioma (0.07) compared to death from glioblastoma (**Table 4**).

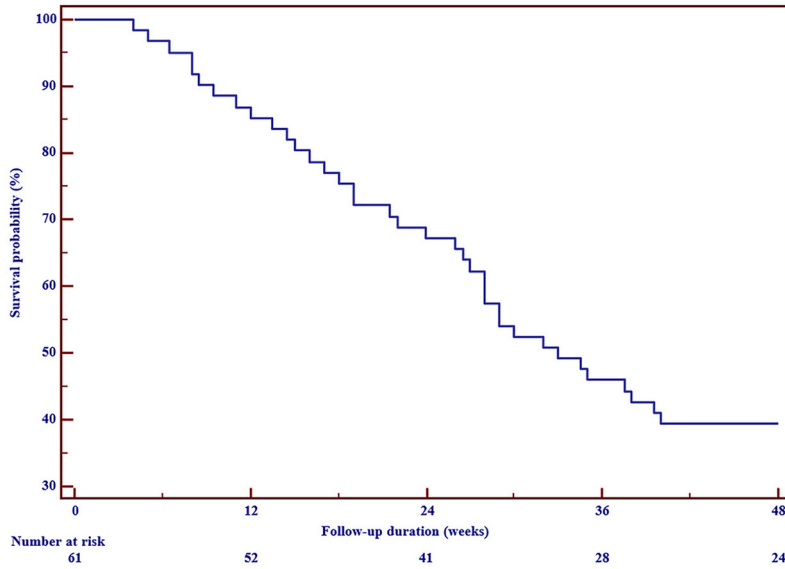
During the follow-up period, 16 (57.1%) women and 21 (63.6%) men died. Within 40 weeks after surgery, survival in men was lower than in women, which significantly affected the median survival: in women it was 34.5 weeks (95% CI - 29-40 weeks), in men - 28 weeks (95% CI - 18-39 weeks). Twelve (42.9%) women and 12 (36.4%) men who lived for more than 60 weeks were under observation (**Fig. 9**). There was no statistically significant difference between male and female survival ( $p = 0.309$ ), but analysis of the mortality risks was found to be higher in men - 1.4 (95% CI - 0.73-2.66) (**Table 5**).

Microsurgical removal of tumors of the lateral and third ventricles was a common treatment method for patients with this pathology. The rapid development of neuroendoscopy over the past 20 years has allowed the development of new minimally invasive options for the treatment of ventricular pathology, which increases the possibilities for surgery of tumors of the lateral and third ventricles. The main advantages of neuroendoscopy over microsurgery are minimal invasiveness and better visualization of deeply located ventricular structures, although traditional microsurgery retains its advantage in terms of bleeding control [1, 3, 5, 7, 8].

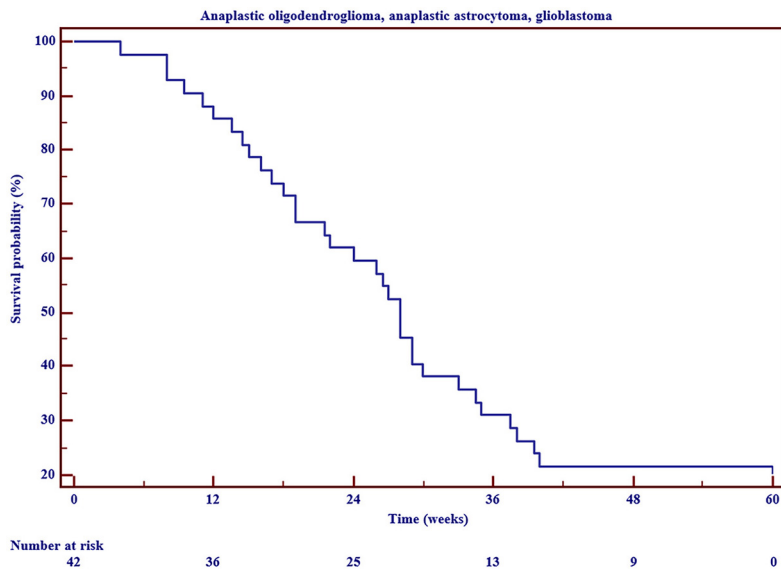
According to observations, primary tumors of the ventricular system are less common in the general population and predominantly benign masses. The peculiarity of these tumors, from the surgical point of view, is the possibility of their gross total resection (GTR) compared to invasive tumors [1, 2, 11]. The possibility and effectiveness of radical endoscopic removal of primary tumors of the third and lateral ventricles of the brain are confirmed by our observations and the results of other authors' studies [1, 2, 4, 5, 6, 10-12]. Such removal is not associated with a high risk of postoperative complications. The majority of patients, have improved the quality and life expectancy, a recurrence-free course and a shorter duration of surgical hospital treatment compared to the "classic" microsurgical technique were noted [3, 7].

The problem of total resection of invasive tumors of the lateral and third ventricles is related to the place of their origin, since they mainly arise from functionally important areas of the brain (thalamus, basal ganglia, etc.). A larger volume of resection may compromise the integrity of these critical neurostructures, resulting in postoperative neurological deficits and disability. Given the fact that the majority of invasive tumors of the ventricular system are the tumors of a high degree of anaplasia (WHO grade III-IV (2021)), achieving the gross total resection (GTR or STR) in combination with radiation and chemotherapy significantly increases the life expectancy of patients.

The use of a fully endoscopic technique minimizes the risk of postoperative complications and creates an optimal surgical corridor.



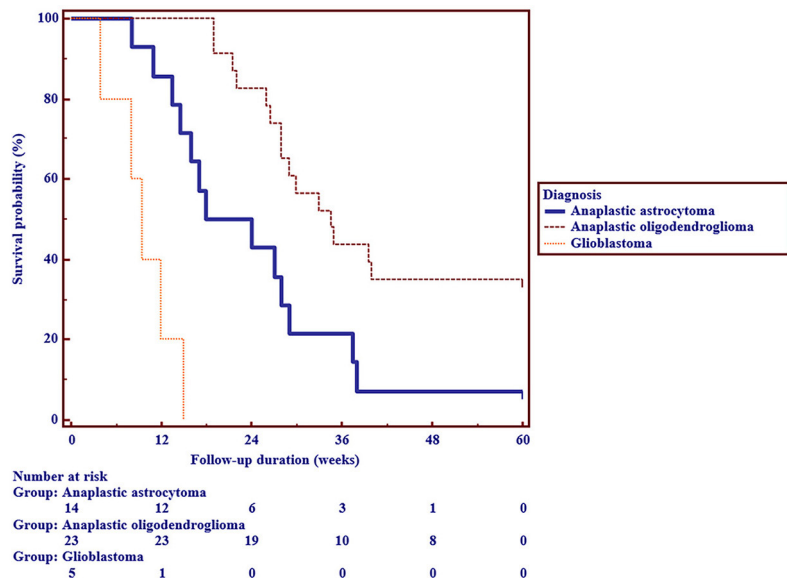
**Fig. 6.** Overall survival (all diagnoses)



**Fig. 7.** Overall survival of patients with anaplastic astrocytoma, oligodendroglioma and glioblastoma (n=42)

**Table 3.** The Result of treatment depending on tumor type

Tumor type	Died		Under observation		Total
	Abs.	%	Abs.	%	
Anaplastic astrocytoma	13	92,86	1	7,14	14
Anaplastic oligodendroglioma	15	65,22	8	34,78	23
Glioblastoma	5	100,00	0	0,00	5
Other tumors	4	21,05	15	78,95	19
Total	37	60,66	24	39,34	61

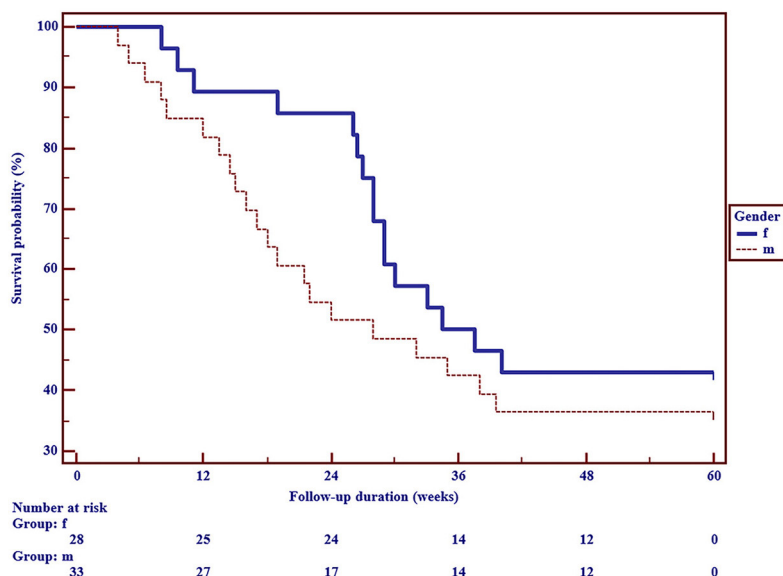


**Fig 8.** Survival depending on tumor type (n=61)

**Table 4.** Mortality risk ratio depending on tumor type

	Anaplastic astrocytoma	Anaplastic oligodendroglioma	Glioblastoma
Anaplastic astrocytoma	-	0,3949 (0,1793-0,8700)	5,4479 (0,3831-77,4824)
Anaplastic oligodendroglioma	2,5323 (1,1494-5,5787)	-	13,7956 (1,0281-185,1106)
Glioblastoma	0,1836 (0,01291-2,6106)	0,07249 (0,005402-0,9726)	-

Note. The 95% CI is given in brackets.



**Fig. 9.** Survival according to gender

**Table 5.** Mortality risk ratio according to gender with 95% confidence interval

	Female	Male
Female	-	1,3962 (0,7327-2,6604)
Male	0,7162 (0,3759-1,3648)	-

Note. The 95% CI is given in brackets.

In our department, for surgical resection of both primary and invasive tumors of the third and lateral ventricles, an endoscopic frontal transcortical transventricular approach is used, which is also used in ventricular pathology surgery in many institutions abroad [3,5,7,8]. Combined with a transforaminal approach, this approach allows the use of natural pathways such as f. Monro to reach the third ventricle through established anatomical landmarks, especially in the setting of hydrocephalus commonly present in patients with tumors of the third and lateral ventricles [5].

Achieving gross total and subtotal resection in 88.85% of interventions in primary tumors and in 82.35% in invasive ones. Other authors [5] reported similar results, achieving total and subtotal resection in 84% of cases.

Various endoscopic techniques can be used when approaching tumors of the ventricular system [12].

The success of the endoscopic endonasal approach to tumors of the third ventricle is comparable to that of radical resection, but it is considered to be associated with a higher risk of infectious complications (meningoencephalitis) and hormonal disorders (diabetes insipidus, etc.) [9, 11].

According to the authors, the use of endoscopic frontal transcortical transventricular approach in patients with primary and invasive tumors of the lateral and third ventricles and obstructive hydrocephalus can be an effective alternative to microsurgical resection using an operating microscope and confirm the clinical effectiveness of endoscopic frontal transcortical transventricular approach [1-12].

### Conclusions

1. The possibility of achieving optimal resection volume of primary and invasive tumors of the third and lateral ventricles makes it possible to recommend anterior endoscopic transcortical transventricular (transforaminal/transchoroidal) approach as an effective method of surgical treatment of these tumors.

2. Radical endoscopic resection as the first stage of combined treatment of patients with malignant tumors of the third and lateral ventricles promotes life expectancy of patients with a minimal risk of postoperative neurological complications, which is comparable to life expectancy of patients with malignant tumors of supratentorial localization.

3. Triventriculocisternostomy is advisable to eliminate obstructive hydrocephalus and prevent the obstruction of CSF circulation in case of postoperative edema or continued growth in invasive tumors of the lateral and third ventricles

### Information disclosure

#### Conflict of interest

The authors declare no conflict of interest.

#### Ethical approval

All procedures performed in studies involving human participants were in accordance with the ethical standards of the institutional and national research committee and with the 1964 Helsinki declaration and its later amendments or comparable ethical standards.

### Informed consent

Informed and voluntary written consent to participate in the study was obtained from all patients.

### Funding

The study was not sponsored.

### References

- Ahmed SI, Javed G, Laghari AA, Bareeqa SB, Aziz K, Khan M, Samar SS, Humera RA, Khan AR, Farooqui MO, Shahbaz A. Third Ventricular Tumors: A Comprehensive Literature Review. *Cureus*. 2018 Oct 5;10(10):e3417. doi: 10.7759/cureus.3417
- Chibbaro S, Di Rocco F, Makiese O, Reiss A, Poczos P, Mirone G, Servadei F, George B, Crafa P, Polivka M, Romano A. Neuroendoscopic management of posterior third ventricle and pineal region tumors: technique, limitation, and possible complication avoidance. *Neurosurg Rev*. 2012 Jul;35(3):331-38; discussion 338-40. doi: 10.1007/s10143-011-0370-1
- Iacoangeli M, di Somma LG, Di Rienzo A, Alvaro L, Nasi D, Scerrati M. Combined endoscopic transforaminal-transchoroidal approach for the treatment of third ventricle colloid cysts. *J Neurosurg*. 2014 Jun;120(6):1471-6. doi: 10.3171/2014.1.JNS131102
- Chibbaro S, Champeaux C, Poczos P, Cardarelli M, Di Rocco F, Iaccarino C, Servadei F, Tigan L, Chaussemy D, George B, Froelich S, Kehrl P, Romano A. Anterior trans-frontal endoscopic management of colloid cyst: an effective, safe, and elegant way of treatment. Case series and technical note from a multicenter prospective study. *Neurosurg Rev*. 2014 Apr;37(2):235-41; discussion 241. doi: 10.1007/s10143-013-0508-4
- Ibáñez-Botella G, Domínguez M, Ros B, De Miguel L, Márquez B, Arráez MA. Endoscopic transchoroidal and transforaminal approaches for resection of third ventricular colloid cysts. *Neurosurg Rev*. 2014 Apr;37(2):227-34; discussion 234. doi: 10.1007/s10143-014-0529-7
- Oppido PA, Fiorindi A, Benvenuti L, Cattani F, Cipri S, Gangemi M, Godano U, Longatti P, Mascari C, Morace E, Tosatto L. Neuroendoscopic biopsy of ventricular tumors: a multicentric experience. *Neurosurg Focus*. 2011 Apr;30(4):E2. doi: 10.3171/2011.1.FOCUS10326
- Roth J, Constantini S. Combined rigid and flexible endoscopy for tumors in the posterior third ventricle. *J Neurosurg*. 2015 Jun;122(6):1341-6. doi: 10.3171/2014.9.JNS141397
- Tawk RG, Akinduro OO, Grewal SS, Brasiliense L, Grand W, Grotenhuis A. Endoscopic Transforaminal Transchoroidal Approach to the Third Ventricle for Cystic and Solid Tumors. *World Neurosurg*. 2020 Feb;134:e453-e459. doi: 10.1016/j.wneu.2019.10.099
- Brusius CV, Bianchin MM, Mira JM, Frigeri T, Kruger M, Grudtner MC, Lenhardt R, Maschke S, Wolfsberger S. Single Burr-Hole Extended Transforaminal Approach for Concurrent Endoscopic Surgery in the Third Ventricle Posterior to the Foramen of Monro and Ventriculostomy: Clinical Series and Planning Steps. *World Neurosurg*. 2021 Jun;150:e1-e11. doi: 10.1016/j.wneu.2021.01.067
- Youngbeom Se, Yong Hwy Kim, Jung Hee Kim, Doo-Sik Kong, Yun-Sik Dho, Ho Kang, Kyung-Min Kim, Jin Wook Kim, Chul-Kee Park Outcomes of the endoscopic endonasal approach for tumors in the third ventricle or invading the third ventricle *J Clin Neurosci*. 2021 Aug; 90:302-310. doi: 10.1016/j.jocn.2021.06.012
- Changfu Zhang, Zhengcun Yan, Xiaodong Wang, Yuping Li, Hengzhu Zhang Quantitative analysis of exposure and surgical maneuverability of three purely endoscopic keyhole approaches to the floor of the third ventricle *J Neurosurg Sci*. 2021 Sep 21. doi: 10.23736/S0390-5616.21.05455-2
- Bolin Liu, Tao Zheng, Wenhai Lv, Yuanzhi Huang, Baofu Li, Baoying Chen, Binrong Wang, Shiming He Endoscopic Endonasal Transsphenoidal Approach for Third Ventriculostomy in the Management of Obstructive Hydrocephalus *J Craniofac Surg*. 2021 Oct 1;32(7):e609-e612. doi: 10.1097/SCS.00000000000007613