

Ukr Neurosurg J. 2022;28(3):33-42
doi: 10.25305/unj.259324

Parasagittal meningiomas: surgical treatment outcomes

Andrii H. Sirko^{1,2}, Vadym A. Perepelytsia^{1,3}

¹ Department of Nervous Diseases and Neurosurgery, Postgraduate Education Division, Dnipropetrovsk State Medical University, Dnipro, Ukraine

² Center for Cerebral Neurosurgery, Mechnikov Dnipropetrovsk Regional Clinical Hospital, Dnipropetrovsk Region Council, Dnipro, Ukraine

³ Endovascular Center, Mechnikov Dnipropetrovsk Regional Clinical Hospital, Dnipropetrovsk Region Council, Dnipro, Ukraine

Received: 17 June 2022

Accepted: 12 August 2022

Address for correspondence

Vadym Perepelytsia, Endovascular Center, Mechnikov Dnipropetrovsk Regional Clinical Hospital, Dnipropetrovsk Region Council, 14 Soborna Sq., Dnipro 49005, Ukraine, e-mail: neuro.perepelitsa@gmail.com

Purpose: to improve the outcomes of surgical treatment of parasagittal meningioma patients by implementing a differentiated approach to the choice of surgical intervention, given the preoperative assessment of patency of the superior sagittal sinus (SSS) and collateral venous circulation.

Materials and methods. Analysis of short-term and long-term outcomes of surgical treatment of 199 patients in the Department of Neurosurgery № 2, Mechnikov Dnipropetrovsk Regional Clinical Hospital was carried out. In the first follow-up period (2000 to 2012), the data were obtained retrospectively (95 cases). In the second follow-up period (2013 to 2021), the data were obtained prospectively (104 cases). The patients were assigned to the groups according to a differentiated approach (implemented in 2013) to the choice of surgical treatment tactics based on preoperative angiographic data (selective cerebral angiography and CT angiography).

Results. In the first follow-up period, the completeness of surgical resection according to Simpson Grading Scale was: type I, 23 (24.2%) cases; type II, 37 (38.9%) cases; type III, 13 (13.7%) cases; type IV, 22 (23.2%) cases. 53.7% of patients had intraoperative or postoperative complications. Among patients with tumors of the middle third of the SSS, 21 (41.2%) had their neurological status improved postoperatively. Mortality rate was 4.2%. 14 (14.7%) patients had further parasagittal meningioma growth after its removal grade II-IV according to Simpson Scale.

In the second follow-up period, the completeness of surgical intervention according to Simpson Scale was: type I, 74 (71.2%) cases; type II, 26 (25%) cases; type III, 2 (1.9%) cases; type IV, 2 (1.9%) cases. 19.2% of patients had intraoperative or postoperative complications. Among the patients with tumors of the middle third of the SSS, 46 (79.3%) patients had postoperative improvement of neurological status. No lethal outcome was reported. 3 (2.9%) patients had further parasagittal meningioma growth after radical surgical removal according to Simpson grade II.

Conclusions. Adequate analysis of instrumental methods of brain study using cerebral vasculature study, application of neuronavigation station (with brain MRI and/or CT angiography data available) and new microsurgical techniques contributed to the completeness of surgery and minimally invasive removal of parasagittal meningioma with reduced intraoperative and postoperative complications, which affected the immediate and long-term treatment outcomes.

Key words: parasagittal meningioma; parasagittal meningioma surgery; superior sagittal sinus; treatment outcomes; completeness; further growth; recurrences.

Introduction

Meningiomas account for 18 to 34% of all primary brain tumors. Parasagittal meningiomas (PM), which occur in 24.3–38.6% of cases [1, 2], constitute a large group of brain meningiomas. The relevance of the PM problem is due to the high frequency of non-radical surgeries and recurrences. According to the literature, the frequency of complete PM removal according to the Simpson I scale (macroscopical total resection of tumor with excision of matrix) [3] averaging 50% (from 21 to 79%), whereas resection according to Simpson I–III is 90% (from 83 to 95%), while resections according to

Simpson IV–V (subtotal removal of PM) are 10% (from 5 to 17%). The recurrence rate of PM after surgical removal averaging about 12% (from 7 to 18%) over a median follow-up period of 5.5 years [1, 4].

It was found that the recurrence rate depends on the radical removal and the degree of malignancy of the PM (Yu.I. Kopyakivskiy. Parasagittal meningiomas [dissertation]. Kyiv (Ukraine): Institute of Neurosurgery named after A. P. Romodanov, National Academy of Medical Sciences of Ukraine; 1961). Thus, with complete removal (Simpson I), recurrences occurred in 1% of observations. Patients with incomplete PM resection

Copyright © 2022 Andrii H. Sirko, Vadym A. Perepelytsia



This work is licensed under a Creative Commons Attribution 4.0 International License
<https://creativecommons.org/licenses/by/4.0/>

(Simpson II–V) had a significantly higher rate of further tumor growth – 19% [1, 4]. Recurrences of PM corresponding to Grade 1 on WHO classification of the central nervous system tumors [5], were registered in 20% of cases with an average follow-up period of 8.7 years (from 2 to 25 years) [4, 6, 7], recurrences of tumors Grade 2 – in 37.5% of cases with an average follow-up period of 7 years (from 1 to 28 years) [8]. Among Grade 3 tumors, more than 50% have relapses after 2 years, and 76% - after 5 years [4].

Postoperative complications occur in an average of 24% of cases (from 16 to 33%). They manifest as hemorrhage in the bed of the removed neoplasm (from 3 to 9%), thrombosis of the superior sagittal sinus (SSS) (from 4 to 15%) and parasagittal veins, later - venous infarction (from 1 to 4%). Most venous infarcts (86%) occur after removal of PM in the middle third of the SSS [1, 4, 6, 9]. Postoperative complications are accompanied by the appearance of a new or worsening of an existing neurological deficit and can lead to a fatal outcome. The frequency of postoperative motor disorders averages 35% in the case of PM of the middle third of the SSS [1, 4]. The incidence of such a postoperative complications as convulsions averages 2% (from 0 to 6%), and infectious complications occur in 3% of cases.

Postoperative lethal outcomes occur in an average of 2% (from 1 to 4%) of observations [1, 2, 4, 6, 9].

Unsatisfactory results of surgical treatment of patients with PM are associated primarily with tumor invasion into the SSS and the difficulty of removing them from the SSS or together with the affected sinus area, as well as with the histobiological features of the PM.

Purpose: to improve the outcomes of surgical treatment of parasagittal meningioma patients by implementing a differentiated approach to the choice of surgical intervention, given the preoperative assessment of patency of the superior sagittal sinus (SSS) and collateral venous circulation.

Materials and methods

Study participants

Analysis of short-term and long-term outcomes of surgical treatment of 199 patients aged 19–78 years (median 55 years) in the Department of Neurosurgery № 2, Mechnikov Dnipropetrovsk Regional Clinical Hospital was carried out, in the period from 2000 to 2021 inclusive.

Written informed consent for the study was obtained from all patients in accordance with the Helsinki Declaration of the World Medical Association on Ethical Principles of Scientific Medical Research Involving Human Subjects (1964–2008), European Society Directive 86/609 on the Participation of Humans in Medical and Biological Research, as well as by order of the Ministry of Health of Ukraine as amended No. 690 of 09/23/2009

The study was approved by the Committee on Ethics and Bioethics of Dnipro State Medical University (research protocol №1 dated February 10, 2020). The work is part of the research work of the Department of Nervous Diseases and Neurosurgery of the Faculty of Postgraduate Education of Dnipro State Medical University №2 dated February 18, 2020.

Inclusion criteria

Criteria for inclusion of patients in the study: patient age ≥ 18 years, parasagittal localization of extracerebral tumor according to the results of computed tomography (CT) and magnetic resonance imaging (MRI), histological verification of meningioma diagnosis.

Characteristics of the group

For comparative analysis, two observation groups were identified.

In the first follow-up period (from 2000 to 2012), data were obtained retrospectively (95 cases), in the second period (from 2013 to 2021) - prospectively (104 cases). The criterion for distribution of patients into groups was the implementation in 2013 of a differentiated approach to the choice of surgical treatment tactics taking into account angiographic data before the surgery (selective cerebral angiography (CAG) and spiral CT angiography (SCT angiography).

CT angiography was performed using a Philips Mx 8000 IDT device (Netherlands). Selective subtraction digital CAG was performed in the endovascular center of Dnipropetrovsk Regional Clinical Hospital named after I.I. Mechnikov using Innova IGS 540 device (GE Healthcare, USA). Contrast agents "Ultravist 370" (Germany), "Visipaque 320" (Ireland) were used for CAG.

Study design

A single-center retro-prospective comparative study. To assess the compliance of both groups in terms of initial characteristics, there were analyzed such data as gender, age, location of the neoplasm in relation to the SSS (anterior, middle, and posterior thirds), tumor invasion into the SSS according to the classification of M.P. Sindou and J.E. Alvernia (I–VI) [6], the degree of malignancy of PM (Grade 1–3 according to WHO classification [5]) and assessment of the patient's functional status according to the Karnofsky scale before surgery.

Planning the stages of surgery and the extent of tumor removal during the follow-up periods

During the first follow-up period, when planning the surgery, the localization of the tumor relative to the SSS and its size were taken into account, patency of the SSS and development of collateral venous outflow tracts were occasionally analyzed, as evidenced by the low frequency of angiographic studies (selective CAG - 10.5%, CT-angiography - 16.8 %). During the preoperative examination, CT scan of the brain was preferred (76.8%). The low frequency of MRI of the brain (45.3%), in particular with intravenous contrast (27.4%), did not make it possible to fully assess the exact localization of the neoplasm, its size and borders, topographic-anatomical relationships with the surrounding brain structures and functionally important areas of the brain.

The choice of surgical intervention volume in the second follow-up period depended primarily on the results of angiographic studies (CT-angiography – 34.6%, invasive CAG – 21.2%, $p=0.004$ and $p=0.04$, respectively, compared to the first period): the patency of the SSS and the presence of a developed system of collateral venous outflow tracts in case of SSS occlusion. In case of meningioma invasion (according to the classification of M.P. Sindou and J.E. Alvernia type I–II, $n=72$), the radical tumor excision along with the matrix was mostly performed (according to Simpson I

classification; 55 (76.4%) patients). In case of damage to one of the walls of the SSS (classified by M.P. Sindou and J.E. Alvernia, type III, n=8), in half of the cases, the method of SSS plasty proposed by us [10] was used to radically remove the PM. In case of damage to two walls of the SSS and preservation of its patency (according to the classification of M.P. Sindou and J.E. Alvernia type IV, n=4), aggressive manipulations could lead to sinus thrombosis and serious complications, therefore, in half of the cases, the nodal part of the tumor was removed, without removing the matrix (according to Simpson III), and the rest of the patients were limited to partial removal of PM (according to Simpson IV). According to the classification of M.P. Sindou and J.E. Alvernia type V-VI (n=20), when the SSS occlusion was confirmed and the collateral venous outflow tracts were identified, in most cases (14 (70%)) meningioma total excision was performed along with the affected part of sinus and falx (according to Simpson I). In 8 (57.1%) of such patients, the technique developed by us was used to safely close marginal SSS defects, with simultaneous preservation of collateral venous outflow tracts [11]. In 100 out of 104 cases (96.2%), a preserved periosteal flap on the pedicle was used, for plastic closure of a defect of the convexal dura mater of the brain [12].

During this observation period, 94.2% of patients underwent surgical interventions using neuronavigation support Stealth Station Treon Plus Medtronic (USA). Prior to surgery, brain MRI data with intravenous contrast and SCT-angiography were integrated into the navigation system and data fusion system (Fusion). The use of the neuronavigation system allowed to clearly plan the soft tissues incision and the borders of craniotomy, taking into account the spread of the nodal component of the tumor and the dural tail. In some cases, burr holes were placed in the projection of large branches of the middle meningeal artery both on the right and on the left, guided by neuronavigation data, which made it possible to reduce tumor bleeding and blood loss volume during craniotomy according to the original method of A.G. Sirko [13,14]. After craniotomy, the data of the neuronavigation system helped clarify the position of the collateral veins and perform a safe incision of the dura mater without iatrogenic damage. Neuronavigation data allowed to more clearly define the boundaries of the tumor-damaged SSS.

Assessment of surgical outcomes

Immediate and long-term results of surgical treatment of PM in two follow-up periods were evaluated. The immediate results of surgical treatment included:

1) the radicality of surgical intervention according to the Simpson grading scale (I-V), as well as in two groups: radical removal (Simpson I) and non-radical removal of PM (Simpson II-V). Both groups were evaluated according to the degree of SSS invasion according to the classification of M.P. Sindou and J.E. Alvernia (I-II, III-IV, V-VI);

2) types and frequency of intraoperative complications: the presence of blood loss and its volume, the need for hemotransfusion and its volume, cerebral edema and hemodynamic complications; types and frequency of postoperative complications: hemorrhage in the bed of the removed neoplasm, venous infarction, infectious complications;

3) types and frequency of reoperations: intracerebral hematoma removal, decompressive craniectomy;

4) assessment of physical function of the patient according to the Karnofsky scale during the first 24 hours after the surgery and at the time of discharge from the hospital;

5) assessment of the dynamics of motor disorders in patients with PM localization in the middle third of the SSS, adjacent to the premotor and motor areas of the cerebral cortex;

6) mortality was assessed within 1 month after surgery.

Long-term results of surgical treatment included:

1) the frequency of recurrences/further growth of PM and the period of their occurrence;

2) the frequency of reoperations due to recurrence/further growth of PM.

All patients after surgery were subject to dynamic follow-up by a neuropathologist and serial SCT/MRI control. The first control MRI of the brain was performed 6 months after the surgery, then annually (in case of a stable neurological picture). In case of new neurological symptoms or deterioration of existing ones, a control brain MRI was performed unscheduled.

"Recurrence" was considered the growth of meningioma after its radical removal (Simpson I). The term "further growth" of a meningioma is used to describe the growth of a residual tumor, as well as to describe the transformation of a low-grade meningioma into a high grade meningioma (for example, from Grade 1 to Grade 2 according to the WHO classification) [15]. In our study, the tumors that had further growth were classified as removed according to the Simpson II-V radicality scale.

Statistical processing of results

Data processing and analysis were performed using Statistica v.10 (StatSoft® Inc., USA, license №STA862D175437Q) and SPSS 17.0 (IBM, USA). The Shapiro-Wilk test was used to verify the conformity of the distribution of quantitative traits to the normal law. In case of normal distribution, parametric characteristics (arithmetic mean value (M), standard error of the arithmetic mean value (m)) and comparison methods (Student's test for independent (t) and dependent (T) samples) were used. In case of abnormal distribution, the median (Me), interquartile range (LQ-HQ) were calculated, and the Mann-Whitney (U) test was used for comparison. The statistical significance of differences in categorical data was assessed by Pearson's chi-squared test without Yates' correction (Yates Chi-square). Determination of the direction and strength of the connection between the features was carried out using correlation analysis with the calculation of the Spearman's rank correlation coefficient (r_s) regardless of their distribution. Differences at $p < 0.05$ were considered statistically significant.

Results and discussion

There was a predominance of female patients in both follow-up periods - 67 (70.5%) and 75 (72.1%) in the first and second periods, respectively ($p=0.804$). Patients were older in the second follow-up period: the average age was 59 (from 49 to 66) years versus 52 (from 47 to 58) years ($p=0.000$) (**Table 1**).

There was no statistically significant difference ($p=0.894$) in the distribution of PM localization in relation to SSS in different periods. In half of the cases, the PM was located in the medial third of the SSS (53.7 and 55.8% of cases in the first and second periods, respectively) (**Table 1**).

Type I according to the classification of M.P. Sindou and J.E. Alvernia prevailed in terms of tumor invasion index into SSS- 63.2 and 61.6% of cases, respectively, in the first and second periods (**Table 1**). No statistically significant differences were found in the distribution of types of tumor invasion into SSS in different observation periods ($p=0.157$).

Assessment of the degree of malignancy of PM showed the prevalence of grade I neoplasms both in the first (85.3%) and in the second (85.6%) follow-up period (**Table 1**), without a statistically significant difference between the indicators ($p=0.633$).

Statistically significant differences between the groups were found only by the age of the patients: the predominance of patients aged 45 to 59 years in the first period and from 60 to 75 years in the second period ($p=0.000$). In other indicators, the difference was statistically insignificant ($p>0.05$), indicating the similarity of the two follow-up periods for the initial characteristics of the patients and the possibility of further comparison of the results.

The average indicator of quality of life and neurological status according to the preoperative Karnofsky Performance Scale in the first period was (68.2 ± 1.0) score and was statistically significantly higher than in the second follow-up period (65.6 ± 0.8) score, $p=0.039$.

Immediate results of surgical treatment of parasagittal meningiomas

Radical (total) surgical removal of PM (Simpson I) statistically significantly prevailed in the second follow-up period - 74 (71.2%) cases versus 23 (24.2%) ($p=0.000$), and non-radical (Simpson II-IV) - in the first (from $p=0.035$ to $p=0.000$) (**Fig. 1**).

As can be seen from the data in **Table 2**, with type I-II invasion of PM into the SSS (according to the classification of M.P. Sindou and J.E. Alvernia) in the second follow-up period, the radicality of surgical removal of the neoplasm (Simpson I) was statistically significantly higher than in the first period - 76.4% versus 34.8% cases ($p=0.000$). In case of type III-IV and V-VI lesions, only non-radical interventions were performed in the first follow-up period, whereas in the second period in 33.3% ($p=0.009$) and 75.0% ($p=0.000$) of cases, total removal of the neoplasm was performed.

Analysis of intraoperative complications (**Table 3**) showed that the average volume of blood loss in the first

Table 1. General characteristics of patients and neoplasms during the study periods

Indicator		1st follow-up period (n=95)	2nd follow-up period (n=104)	Statistical significance of the difference between periods
Gender	female	67 (70,5%)	75 (72,1%)	$\chi^2=0,06$; $p = 0,804$
	male	28 (29,5%)	29 (27,9%)	
Age, years	18-44	17 (17,9%)	19 (18,3%)	$\chi^2=16,84$; $p = 0,000$
	45-59	57 (60,0%)	35 (33,6%)	
	60-75	21 (22,1%)	50 (48,1%)	
	average	52 (47-58)	59 (49-66)	$U=3651$; $p = 0,000$
Tumor localization to SSS	anterior third	29 (30,5%)	32 (30,8%)	$\chi^2=0,22$; $p = 0,894$
	medial third	51 (53,7%)	58 (55,8%)	
	posterior third	15 (15,8%)	14 (13,4%)	
SSS lesion according to M.P. Sindou and J.E. Alvernia	I	60 (63,2%)	64 (61,6%)	$\chi^2=7,98$; $p = 0,157$
	II	6 (6,3%)	8 (7,7%)	
	III	8 (8,4%)	8 (7,7%)	
	IV	10 (10,5%)	4 (3,8%)	
	V	2 (2,1%)	10 (9,6%)	
	VI	9 (9,5%)	10 (9,6%)	
Degree of malignancy	Grade I	81 (85,3%)	89 (85,6%)	$\chi^2=0,91$; $p = 0,633$
	Grade II	5 (5,2%)	8 (7,7%)	
	Grade III	9 (9,5%)	7 (6,7%)	
Assessment according Karnofsky Performance Scale, score		$68,2\pm 1,0$	$65,6\pm 0,8$	$t=2,07$; $p = 0,039$

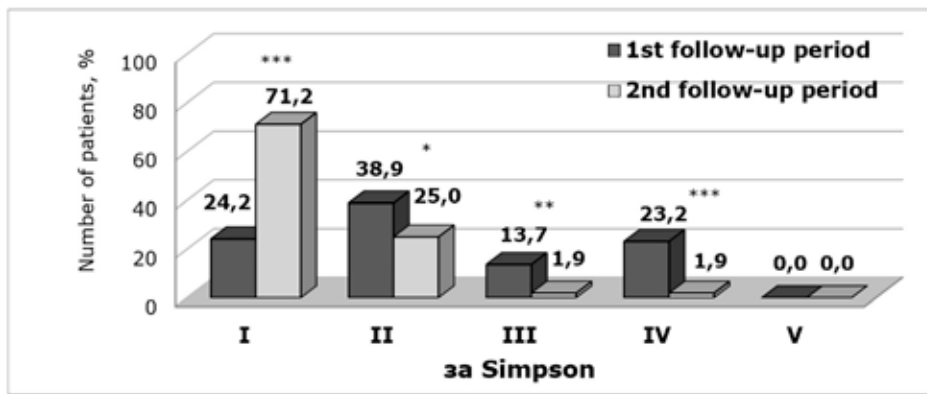


Fig. 1. Frequency of cases of radical surgical removal of parasagittal meningioma according to the Simpson classification in different follow-up periods: the difference between indicators in different periods is statistically significant: * - $p=0.035$; ** - $p=0.002$; *** - $p=0.000$ (according to the χ^2 test)

Table 2. Radicality of surgical intervention depending on the extent of parasagittal meningioma invasion into the superior sagittal sinus

Radicality of meningioma removal	SSS lesion according to the classification of M.P. Sindou and J.E. Alvernia					
	I-II		III- IV		V- VI	
	1 st period (n=66)	2 nd period (n=72)	1 st period (n=18)	2 nd period (n=12)	1 st period (n=11)	2 nd period (n=20)
Simpson I	23 (34,8%)	55 (76,4%)	-	4 (33,3%)	-	15 (75,0%)
Simpson II-IV	43 (65,2%)	17 (23,6%)	18 (100,0)	8 (66,7%)	11 (100,0%)	5 (25,0%)
Statistical significance of the difference between periods	$\chi^2=24,18$; $p=0,000$		$\chi^2=6,92$; $p=0,009$		$\chi^2=15,98$; $p=0,000$	

period was statistically significantly higher ($p=0.019$) than in the second period, respectively, a statistically significantly greater number of patients required blood transfusion in the first period ($p=0.014$). However, the average volume of blood transfusion of fresh frozen plasma and packed red blood cells was greater for patients in the second period ($p=0.025$ and $p=0.221$, respectively). Correlation analysis revealed the presence of a statistically significant directly proportional relationship of average strength between the volume of blood loss and blood transfusion in the second period ($r_s = 0.63$, $p=0.013$ for packed red blood cells and $r_s = 0.56$, $p=0.013$ for plasma) and the absence of such dependence during surgery in the first period ($r_s = 0.14$, $p=0.499$ and $r_s = 0.001$, $p=0.998$), which confirms the adequacy of transfusion care in the second follow-up period.

The volume of intraoperative blood loss in both periods was associated with the tumor size ($r_s = 0.59$, $p=0.000$ and $r_s = 0.57$, $p=0.000$) and the degree of SSS invasion according to the classification of M.P. Sindou and J.E. Alvernia VI ($r_s = 0.29$, $p=0.004$ and $r_s = 0.20$, $p=0.042$). In the first period, a weak but statistically significant correlation between blood loss volume and degree of malignancy ($r_s = 0.23$, $p=0.026$), completeness

of Simpson IV tumor resection ($r_s = 0.21$, $p=0.039$), as well as a moderate relationship with the development of intraoperative cerebral edema ($r_s = 0.40$, $p=0.000$) were found. In the second period, the volume of blood loss was greater during excision of the occluded portion of the SSS ($r_s = 0.31$, $p=0.002$), as well as when performing plasty of the SSS wall as a whole ($r_s = 0.23$, $p=0.019$) and periosteum ($r_s = 0.29$, $p=0.003$).

Intraoperative cerebral edema in the first period occurred statistically significantly ($p=0.003$) more often. Intraoperative hemodynamic complications in the first period were noted in 14 (14.7%) patients, while in the second - only in 2 (1.9%) ($p=0.001$).

According to the data of the correlation analysis, it was established that in the first period of observation there was a statistically significant directly proportional relationship of average strength between the degree of tumor invasion in the SSS according to the classification of M.P. Sindou and J.E. Alvernia VI and the occurrence of intraoperative cerebral edema or hemodynamic complications ($r_s = 0.36$ and $r_s = 0.37$, $p=0.000$), in the second period - only with the development of cerebral edema ($r_s = 0.30$, $p=0.002$). In addition, brain edema intraoperatively in the second follow-up period was weakly but statistically significantly associated with the

Table 3. Characteristics of perioperative complications during the study periods

Indicator	1 st period (n=95)	2 nd period (n=104)	Statistical significance of the difference between periods
Intraoperative complications			
Volume of blood loss, ml	675,8±45,5	536,1±38,2	t=2,37; p=0,019
Blood transfusion: number of cases	34 (35,8%)	21 (20,2%)	$\chi^2=6,04$; p=0,014
Volume of packed red blood cells, ml	524,3±28,5	637,1±84,1	t=1,27; p=0,221
Volume of fresh frozen plasma, ml	387,7±28,8	563,2±67,7	t=2,38; p=0,025
Cerebral edema	10 (10,5%)	1 (1,0%)	$\chi^2=8,70$; p=0,003
Hemodynamic complications	14 (14,7%)	2 (1,9%)	$\chi^2=11,03$; p=0,001
Postsurgical complications			
Hemorrhage in the removed tumor bed	6 (6,3%)	12 (11,5%)	$\chi^2=1,65$; p=0,199
Epidural hematoma	-	1 (1,0%)	$\chi^2=0,92$; p=0,338
Venous infarction	17 (17,9%)	4 (3,8%)	$\chi^2=10,38$; p=0,001
Infectious complications	4 (4,2%)	-	$\chi^2=4,47$; p=0,035

degree of tumor malignancy ($r_s = 0.22$, $p = 0.025$), as well as with surgical excision of the occluded portion of the SSS ($r_s = 0.20$, $p = 0.043$).

Such postoperative complication as hemorrhage into the bed of the removed tumor, occurred less frequently in the first period than in the second, 6.3% versus 11.5% of cases, but without a statistically significant difference between periods ($p = 0.199$) (**Table 3**). A single case of postoperative epidural hematoma occurred only in the second follow-up period ($p = 0.338$). Cases of venous infarction ($p = 0.001$), meningitis or wound liquorrhea as causes of infectious complications ($p = 0.035$) were statistically significantly more frequent in the first period.

When analyzing the data in the first period of follow-up, a close relationship between the degree of SSS lesion according to the classification of M.P. Sindou and J.E. Alvernia V and the development of postoperative meningitis or wound liquorrhea ($r_s = 0.70$, $p = 0.000$), as well as a statistically significant weak correlation between the tumor location in the medial /posterior third of the SSS and an increase in cerebral edema and the development of venous infarction ($r_s = 0.21$, $p = 0.038$). The use of BrainLab neuronavigation contributed to the decrease of cases of these complications ($r_s = -0.22$, $p = 0.035$).

During the second follow-up period, there was a statistically significant direct proportional relationship of average strength between the development of such postoperative complications as an increase of cerebral edema and venous infarction and the SSS muscle plastic surgery ($r_s = 0.49$, $p = 0.000$), as well as the completeness of tumor resection according to Simpson III ($r_s = 0.34$, $p = 0.000$). With the lesion of the SSS according to the classification of M.P. Sindou and J.E. Alvernia type IV was statistically significantly associated with an increase of cerebral edema and the development of venous

infarction ($r_s = 0.22$, $p = 0.025$), and with the lesion of the SSS type VI - the occurrence of a hematoma in the bed of the tumor ($r_s = 0.20$, $p = 0.045$).

Three (3.2%) patients required reoperation in the first period, 2 (2.1%) of them underwent blood removal from the bed of the removed tumor without drainage, 1 (1.1%) had decompressive craniectomy. In the second period, repeated surgical intervention was performed in 4 (3.8%) patients: 2 (1.9%) had removal of hemorrhage from the bed of the removed tumor without installing a drainage system, another 2 (1.9%) - with installation of a tidal system. Comparative analysis of the data of repeated surgical interventions revealed no statistically significant difference between follow-up periods (for all comparisons $p > 0.05$).

The neurological status of 109 patients with PM of the medial third of the SSS before and after surgery was analyzed in detail, 51 of them in the first period, 58 in the second. The clinical and neurological condition before surgery was characterized by manifestation of headache in almost all patients (97.2%), dizziness - in 88.1%, focal seizures - in 26.6%, cognitive deficit - in 45.9%, movement disorders in the limbs (hemiparesis) and sensitivity (hemihypesthesia) - in 58.7 and 50.5%, respectively. There were no statistically significant differences in the clinical and neurological condition of patients before surgery in different observation periods (**Table 4**).

After surgery, the neurological status of patients in the first follow-up period improved in 21 (41.2%) patients, worsened in 26 (50.1%), and remained unchanged in the rest (**Table 5**). Motor disorders increased in almost half of the patients (47.1%).

In the second period, improvement of the neurological condition after surgery was observed in the majority (79.3%) of patients ($p = 0.000$ compared

Table 4. Frequency of neurological disorders in patients with parasagittal meningiomas of the medial third of the superior sagittal sinus before surgery in different follow-up periods

Indicator	1 st study period (n=51)	2 nd study period (n=58)	Statistical significance of the difference between periods
Headache	50 (98,0%)	56 (96,6%)	$\chi^2=0,22$; $p=0,636$
Focal seizures	13 (25,5%)	16 (27,6%)	$\chi^2=0,06$; $p=0,805$
Dizziness	47 (92,2%)	49 (84,5%)	$\chi^2=1,52$; $p=0,217$
Cognitive deficit	21 (41,2%)	29 (50,0%)	$\chi^2=0,85$; $p=0,356$
Hemiparesis	30 (58,8%)	34 (58,6%)	$\chi^2=0,0005$; $p=0,983$
Hemihyesthesia	30 (58,8%)	25 (43,1%)	$\chi^2=2,68$; $p=0,101$

Table 5. Changes in the neurological status of patients with parasagittal meningiomas of the medial third of the superior sagittal sinus after surgery

Indicator		1 st study period (n=51)	2 nd study period (n=58)	Statistical significance of the difference between periods
Neurological status	improvement	21 (41,2%)	46 (79,3%)	$\chi^2=16,66$; $p=0,000$
	unchanged	4 (7,8%)	5 (8,6%)	$\chi^2=0,02$; $p=0,883$
	deterioration	26 (50,1%)	7 (12,1%)	$\chi^2=19,47$; $p=0,000$
Increase in motor disorders		24 (47,1%)	16 (27,6%)	$\chi^2=4,43$; $p=0,035$
Speech disorders		9 (17,6%)	4 (6,9%)	$\chi^2=2,99$; $p=0,084$
Sensory disturbances		27 (52,9%)	10 (17,2%)	$\chi^2=15,42$; $p=0,000$
Depression of consciousness		3 (5,9%)	–	$\chi^2=3,51$; $p=0,061$
Pelvic organs dysfunction		5 (9,8%)	–	$\chi^2=5,96$; $p=0,015$
Upper extremity strength, point		3,76±0,21	4,26±0,14	$t=1,99$; $p=0,049$
Lower extremity strength, point		3,49±0,22	4,21±0,14	$t=2,77$; $p=0,007$

to the first period), deterioration in a much smaller number of patients compared to the first period (12.1%, $p=0.000$). Aggravation of neurological deficit in the form of motor disorders was registered in 16 (27.6%) patients ($p=0.035$). The average score of paresis in the upper and lower extremities exceeded that in the first period ($p=0.049$ and $p=0.007$, respectively).

In general, the analysis of changes in quality of life and neurological status in all studied cases of surgical treatment of patients with PM ($n=199$) showed a decrease in the mean score according to the Karnofsky scale in the first day after surgery in the first period by 7.2% ($p=0.016$) and its increase of 6.7% ($p=0.005$) in the second period. At discharge from the hospital, the mean score according to the Karnofsky scale in the first period reset to the initial level ((69.5±2.1) points, $p=0.571$) and significantly improved in the second period (by 22.7% to (80.5± 1.2) points, $p=0.000$). Thus, even with a slightly reduced level of quality of life before surgery in the second period (**Table 1**), the use of proposed diagnostic methods and surgical intervention yielded better results than in the first group ($p=0.000$).

According to the data of correlation analysis, in both observation periods, a statistically significant inversely proportional correlation was established between the neurological level according to the Karnofsky scale in the first day after surgery, as well as at discharge and the

postoperative increase in cerebral edema, development of hematoma in the tumor bed and venous infarction (from $r_s = -0.20$, $p=0.048$ to $r_s = -0.47$, $p=0.000$) (**Table 6**).

In the first follow-up period, a statistically significant inversely proportional relationship was found between the neurological condition according to the Karnofsky scale in the first day after surgery and the intraoperative development of cerebral edema, hemodynamic disorders and the degree of SSS invasion (according to the classification of M.P. Sindou and J.E. Alvernia IV), as well as between the neurological condition and intraoperative complications at the time of discharge from the hospital, in particular with the development of cerebral edema, hemodynamic abnormalities, the volume of intraoperative blood loss. In addition, in the first period, the deterioration of the patient's neurological condition after surgery was noted in the case of localization of the tumor in the middle/posterior third of the SSS ($r_s = 0.23$, $p=0.026$), while the use of BrainLab neuronavigation was statistically significantly associated with the improvement of the condition (correlation of the average strength, $r_s = 0.33$, $p=0.001$).

In the second follow-up period, a statistically significant inversely proportional weak correlation was also found between the level of neurological status according to the Karnofsky scale at discharge and the volume of intraoperative blood loss ($r_s = -0.22$; $p=0.028$).

Table 6. Correlations between the neurological level of patients with parasagittal meningiomas according to the Karnofsky scale and perioperative complications

Complications	Assessment of the patient's neurological status according to the Karnofsky scale			
	1 st study period		2nd study period	
	1st day after surgery	At discharge	1st day after surgery	At discharge
Intraoperative				
Increase in cerebral edema	-0,50 (p=0,000)	-0,49 (p=0,000)	n/r	n/r
Volume of blood loss	-0,41 (p=0,000)	-0,37 (p=0,000)	-0,23 (p=0,021)	-0,22 (p=0,028)
Hemodynamic abnormalities	-0,22 (p=0,029)	-0,25 (p=0,014)	n/r	n/r
Degree of SSS invasion (according f M.P. Sindou and J.E. Alvernia IV classification)	-0,22 (p=0,029)	n/r	n/r	n/r
Postoperative				
Increase in cerebral edema	-0,47 (p=0,000)	-0,45 (p=0,000)	-0,32 (p=0,001)	-0,28 (p=0,004)
Hematoma in the tumor bed	-0,22 (p=0,029)	-0,20 (p=0,048)	-0,37 (p=0,000)	-0,37 (p=0,000)
Venous infarction	-0,47 (p=0,000)	-0,45 (p=0,000)	-0,32 (p=0,001)	-0,28 (p=0,004)

Note: p - is the level of statistical significance of correlation coefficient; n/r - correlation coefficient is statistically insignificant (p>0.05).

Postoperative mortality during the first month after surgery was recorded only in the first follow-up period in 4 (4.2%) patients ($\chi^2=4.47$, p=0.035). Median day of death - 8 (from 7.5 to 17.5) days. Lethality was directly proportionally associated with the development of such postoperative complications as increased cerebral edema (r=0.31, p=0.002), venous infarction (r=0.31, p=0.002), meningitis (r=0.22, p= 0.035) and wound liquorrhea (r=0.22, p=0.035).

Long-term outcomes of surgical treatment of parasagittal meningiomas

In the first period, 14 (14.7%) cases of further PM growth were registered, while in the second period there were 5.1 times less (3 (2.9%), $\chi^2=8.93$, p=0.003).

Most of the tumors that recurred in the first period were grade I malignancy (Grade I) - 11 (78.6%), 1 (7.1%) - Grade II, and 2 (14.3%) - Grade III. All surgical interventions performed were non-radical: Simpson II - 8 (57.1%) cases, Simpson III - 2 (14.3%), Simpson IV - 4 (28.6%). The period of further tumor growth averaged 1213 (from 618 to 2946) days, or 40.4 (from 20.6 to 98.2) months. All 14 patients with meningiomas with further growth were operated on again, 3 (21.4%) of them - twice, 11 (78.6%) - once.

In the second period, out of 3 recorded cases of further growth of PM Grade I had 2 (66.7%) tumors, Grade II - 1 (33.3%). In all cases, non-radical Simpson II surgeries were initially performed. The period of further tumor growth averaged 1322 (from 987 to 1457) days, or 44.1 (from 32.9 to 48.6) months, and was not statistically significantly different from the indicators in the first

follow-up period (U=21.0, p=1.00). All 3 patients with PM with further growth were operated on again (once).

Given the increased radicality of surgical interventions, a natural improvement in the long-term results of PM treatment in the second follow-up period was found. In our study, only the further tumor growth was registered, but its occurrence is also characteristic of benign meningiomas (Grade I) in 2 cases after their radical removal (Simpson II), while progression was absent after their non-radical removal (Simpson III-V).

The results obtained indicate that the change in the tactics of surgical intervention in the second follow-up period (2013-2021) not only did not improve the rate of hemorrhages in the bed of the removed tumor, but even increased their incidence to 11.5%. This is primarily due to a more radical approach to PM removal, especially in patients with SSS lesions according to the classification of M.P. Sindou and J.E. Alvernia III-IV and V-VI. The desire for total tumor removal with the need for excision of the affected area of the SSS and subsequent surgical manipulations on it is associated with a high risk of both intraoperative and postoperative bleeding, which affected the early postoperative results. Despite this, such radicalism has unconditional advantages when evaluating not only other categories of immediate, but also long-term outcomes of surgical treatment. The frequency of hemorrhages in the bed of the removed tumor did not affect the frequency of reoperations, as evidenced by the absence of statistically significant difference between the follow-up periods. However, despite the radicalism of the surgical intervention in the second follow-up period,

the number of cases of venous infarction decreased significantly (3.8%), which is explained by the adequate preoperative analysis of the results of CT angiography/invasive CAG with the definition of the topography of the draining veins and the tracts of collateral venous blood circulation, using neuronavigation and improved microsurgical techniques [10–14], which made it possible to prevent iatrogenic damage to venous structures without limiting the radicalism of surgical removal of PM. In addition to the mentioned advantages, the use of brain MRI data with/without intravenous contrast enhancement made it possible to assess the topographical and anatomical relationships of the tumor with the adjacent brain tissue. Analysis of neoplasm localization, neuroimaging characteristics of both the tumor and its impact on the adjacent brain tissue significantly influenced the preoperative planning. Data of instrumental examinations using the neuronavigation system intraoperatively allowed to control tumor resection borders while preserving functionally important brain areas, which contributed to achieving better results of the patient's physical functioning according to the Karnofsky scale and a decrease in the severity of motor deficit in the second follow-up period.

Due to a differentiated approach to the surgical treatment of PM in the second follow-up period, it was possible to achieve an increase in the radicality of the intervention in all subgroups of patients according to the type of SSS lesion according to the classification of M.P. Sindou and J.E. Alvernia (I-II, III-IV and V-VI). In meningioma invasion type I-II according to the classification of M.P. Sindou and J.E. Alvernia in most cases (76.4%) radical excision of the neoplasm with its matrix (Simpson I) was performed. In case of confirmation of the SSS occlusion (according to the classification of M.P. Sindou and J.E. Alvernia V-VI) and with the help of angiographic research methods, the formed pathways of collateral blood circulation were revealed; in 70% of the observations, total removal of the PM (Simpson I) along with the affected part of the sinus and falx was achieved, avoiding violations venous outflow, and therefore possible complications. In both subgroups of patients, the radicality of the surgical intervention required resection of the convexital dura mater affected by the tumor. In this case, the membrane plasty was performed with a previously prepared periosteal pedicled flap, preventing serious infectious complications, as evidenced by their absence in the second follow-up period. The least sufficient, but statistically significant increase in the radicality of surgical intervention (in the absence of total removal according to Simpson I in the first follow-up period) was recorded in patients with SSS lesions according to the classification of M.P. Sindou and J.E. Alvernia III-IV. In case of damage to one wall of the SSS in half of the patients (50%), the method of SSS plasty proposed by us [10] was used to achieve radical removal of the PM. If two walls of the SSS were damaged and its patency was preserved, aggressive manipulations could lead to sinus thrombosis and serious complications, therefore, not in all cases we managed to completely remove the tumor and perform plastic surgery of the SSS walls. Part of the tumor often remained (Simpson III, IV). We did not perform reconstructive surgery on

the SSS, since the literature sources [6,16] report high risk associated with its reconstruction, which is not comparable to the expected result. According to foreign authors, during angiographic follow-up (from 2 weeks to 2 years after the SSS reconstruction with autoshunt (great saphenous vein, external jugular vein, the fascia lata and radial artery)) it was found that in 45% of cases autoshunts were thrombosed, and in 55% - functioned satisfactorily. In patients with artificial grafts (Gore Tex and PTFE), their thrombosis was recorded in almost 100% of cases, severe neurological complications in 10%. Therefore, in most patients, the tactics of subtotal removal of PM was chosen in case of SSS lesion according to the M.P. Sindou and J.E. Alvernia III-IV classification followed by irradiation [17,18] or radical excision after gradual complete occlusion of the sinus and development of adequate collateral circulation.

The problem of recurrence of benign meningiomas (Grade I) after their radical removal (Simpson II) and the absence of further growth in some cases after non-radical removal (Simpson III–V) requires in-depth study of the immunohistochemical and molecular biological features of SSS meningiomas, which will be the subject of our further of research.

Conclusions

1. In addition to brain computed tomography, preoperative diagnosis of parasagittal meningiomas must include MRI with intravenous enhancement to determine the nature of the tumor spread to the superior sagittal sinus, the convexital dura mater and falx cerebri, as well as the nature of invasion into the brain.

2. Preoperative diagnosis of parasagittal meningiomas, which, according to CT/MRI of the brain (with intravenous contrast), have signs of invasion into the superior sagittal sinus, must necessarily include an assessment of the patency of the superior sagittal sinus according to the data of selective CAG or CT-angiography.

3. Preoperative diagnosis of parasagittal meningiomas, which, according to CT, CT-angiography or MRI of the brain (with intravenous contrast), have signs of invasion into the superior sagittal sinus according to the classification of M.P. Sindou and J.E. Alvernia V-VI, must include selective CAG to confirm sinus occlusion and identify all collateral pathways.

4. In case of occlusion of the superior sagittal sinus by a parasagittal meningioma (according to the classification of M.P. Sindou and J.E. Alvernia V-VI), information on collateral venous circulation data (according to the data of invasive CAG) is extremely important when planning a surgical intervention, which makes it possible to avoid iatrogenic damage to functionally important veins and areas of the superior sagittal sinus that are functioning.

5. Adequate analysis of instrumental methods of brain research using the option of cerebral vascular system study, a neuronavigation station (in the presence of brain MRI and/or CT angiography data) and new microsurgical techniques contributes to increasing the radicality and minimally traumatic removal of parasagittal meningioma and reducing the risk of intraoperative and postoperative complications, which affects immediate and long-term treatment results.

Disclosure

Conflict of interest

The authors declare no conflict of interest.

Ethical approval

All procedures performed in studies involving human participants were in accordance with the ethical standards of the institutional and national research committee and with the 1964 Helsinki declaration and its later amendments or comparable ethical standards.

Informed consent

Informed and voluntary written consent to participate in the study was obtained from all patients.

Funding

The study was not sponsored.

References

- Gatterbauer B, Gevsek S, Höftberger R, Lütgendorf-Caucig C, Ertl A, Mallouhi A, et al. Multimodal treatment of parasagittal meningiomas: a single-center experience. *J Neurosurg.* 2017 Dec;127(6):1249-1256. doi: 10.3171/2016.9.JNS161859
- Zeeshan Q, Patel A, Cheng CY, Zhao NH, Barber J, Ghodke BV, et al. Resection of Meningiomas Involving Major Dural Venous Sinuses: Classification, Technique, and Long-Term Results. *World Neurosurg.* 2019 May;125:e521-e536. doi: 10.1016/j.wneu.2019.01.128
- Gousias K, Schramm J, Simon M. The Simpson grading revisited: aggressive surgery and its place in modern meningioma management. *J Neurosurg.* 2016 Sep;125(3):551-60. doi: 10.3171/2015.9.JNS15754
- Giordan E, Sorenson TJ, Lanzino G. Optimal surgical strategy for meningiomas involving the superior sagittal sinus: a systematic review. *Neurosurg Rev.* 2020 Apr;43(2):525-535. doi: 10.1007/s10143-018-1026-1
- Louis DN, Perry A, Reifenberger G, von Deimling A, Figarella-Branger D, Cavenee WK, et al. The 2016 World Health Organization Classification of Tumors of the Central Nervous System: a summary. *Acta Neuropathol.* 2016 Jun;131(6):803-20. doi: 10.1007/s00401-016-1545-1
- Ricci A, Di Vitantonio H, De Paulis D, Del Maestro M, Gallieni M, Dechordi SR, et al. Parasagittal meningiomas: Our surgical experience and the reconstruction technique of the superior sagittal sinus. *Surg Neurol Int.* 2017 Jan 19;8:1. doi: 10.4103/2152-7806.198728
- Yin T, Gu J, Huang Y, Wei L, Gao J, Wang S. Assessment and Treatment of Peritumoral Cortical Veins in Parasagittal Meningiomas with Application of 3-Dimensional Imaging Fusion Model. *World Neurosurg.* 2017 Aug;104:220-228. doi: 10.1016/j.wneu.2017.04.145
- Escribano Mesa JA, Alonso Morillejo E, Parrón Carreño T, Huete Allut A, Narro Donate JM, Méndez Román P, et al. Risk of Recurrence in Operated Parasagittal Meningiomas: A Logistic Binary Regression Model. *World Neurosurg.* 2018 Feb;110: e112-e118. doi: 10.1016/j.wneu.2017.10.087
- Bi N, Xu RX, Liu RY, Wu CM, Wang J, Chen WD, et al. Microsurgical treatment for parasagittal meningioma in the central gyrus region. *Oncol Lett.* 2013 Sep;6(3):781-784. doi: 10.3892/ol.2013.1429
- Sirko AH, Perepelytsia VA, vynakhidnyk; Derzhavna Ustanova "Instytut neirokhirurhii im. akad. A.P. Romodanova Natsionalnoi Akademii Medychnykh Nauk Ukrainy", vlasnyk. Sposib plastyky defektu verkhnoho sahitalnoho synusa (VSS) pislia vydalennia parasahitalnoi meninhiomy (PM), yaka yklykaiuchy yoho okliuzii. Ukraine patent 146105. 2020 Aug 03.
- Sirko AH, Perepelytsia VA, vynakhidnyk; Derzhavna Ustanova "Instytut neirokhirurhii im. akad. A.P. Romodanova Natsionalnoi Akademii Medychnykh Nauk Ukrainy", vlasnyk. Sposib plastychnoho zakryttia kraiovoho defektu verkhnoho sahitalnoho synusa (VSS) pislia totalnoho vydalennia (hratsiia i za klasyfikatsiieiu Simpson) parasahitalnoi meninhiomy (PM), yaka vyklykaie obturatsiiu VSS (hradatsiia VI za klasyfikatsiieiu Bonnel ta Botchi), iz zberezheniam shliakhiv kolateralnoho krovotoku. Ukraine patent 146106. 2020 Aug 03
- Sirko AH, Romanukha DM, vynakhidnyk; Derzhavna Ustanova "Instytut neirokhirurhii im. akad. A.P. Romodanova Natsionalnoi Akademii Medychnykh Nauk Ukrainy", vlasnyk. Sposib plastyky defektu tverdoi mozkovoi obolonky pry retrosyhmopodibnomu dostupi. Ukraine patent 141382. 2019 Jul 18.
- Sirko AH, Kyrpa IYu, vynakhidnyk; Derzhavna Ustanova "Instytut neirokhirurhii im. akad. A.P. Romodanova Natsionalnoi Akademii Medychnykh Nauk Ukrainy", vlasnyk. Method for treating convexity supratentorial meningioma. Ukraine patent 102963. 2015 Jun 02.
- Sirko AG, Zorin NA, Novik YuE, Kirpa IYu, Shpohnka VI. Stealth Station® Treon®Plus neuronavigation system in surgery of intracranial meningiomas. *Ukrainian Neurosurgical Journal.* 2010;(1):39-46. doi:10.25305/unj.88763
- Buerki RA, Horbinski CM, Kruser T, Horowitz PM, James CD, Lukas RV. An overview of meningiomas. *Future Oncol.* 2018 Sep;14(21):2161-2177. doi: 10.2217/fon-2018-0006
- Abdallah OI, Clark D, Essibayi MA. Surgical Reconstruction of a Traumatic Superior Sagittal Sinus Injury Using Synthetic Vascular Graft in a Resource-Limited Civilian Field Hospital During the Syrian Civil War. *World Neurosurg.* 2022 Mar;159:126-129. doi: 10.1016/j.wneu.2021.12.116
- Li D, Jiang P, Xu S, Li C, Xi S, Zhang J, et al. Survival impacts of extent of resection and adjuvant radiotherapy for the modern management of high-grade meningiomas. *J Neurooncol.* 2019 Oct;145(1):125-134. doi: 10.1007/s11060-019-03278-w
- Zhu H, Bi WL, Aizer A, Hua L, Tian M, Den J, et al. Efficacy of adjuvant radiotherapy for atypical and anaplastic meningioma. *Cancer Med.* 2019 Jan;8(1):13-20. doi: 10.1002/cam4.1531
- Bir SC, Konar SK, Maiti TK, Thakur JD, Guthikonda B, Nanda A. Utility of Neuronavigation in Intracranial Meningioma Resection: A Single-Center Retrospective Study. *World Neurosurg.* 2016 Jun;90:546-555.e1. doi: 10.1016/j.wneu.2015.12.101
- Champeaux C, Jecko V, Houston D, Thorne L, Dunn L, Fersht N, et al. Malignant Meningioma: An International Multicentre Retrospective Study. *Neurosurgery.* 2019 Sep 1;85(3):E461-E469. doi: 10.1093/neuros/nyy610
- Di Vitantonio H, De Paulis D, Del Maestro M, Ricci A, Dechordi SR, Marzi S, et al. Dural repair using autologous fat: Our experience and review of the literature. *Surg Neurol Int.* 2016 Jul 7;7(Suppl 16):S463-8. doi: 10.4103/2152-7806.185777
- Goldbrunner R, Minniti G, Preusser M, Jenkinson MD, Sallabanda K, Houdart E, et al. EANO guidelines for the diagnosis and treatment of meningiomas. *Lancet Oncol.* 2016 Sep;17(9):e383-91. doi: 10.1016/S1470-2045(16)30321-7
- Lemée JM, Corniola MV, Meling TR. Benefits of re-do surgery for recurrent intracranial meningiomas. *Sci Rep.* 2020 Jan 15;10(1):303. doi: 10.1038/s41598-019-57254-5
- Tomasi SO, Umana GE, Scalia G, Raudino G, Graziano F, Palmisciano P, et al. The Superficial Anastomosing Veins of the Human Brain Cortex: A Microneurosurgical Anatomical Study. *Front Surg.* 2022 Jan 10;8:817002. doi: 10.3389/fsurg.2021.817002
- von Spreckelsen N, Waldt N, Timmer M, Goertz L, Reinecke D, Laukamp K, et al. Clinical Characteristics and Magnetic Resonance Imaging-Based Prediction of the KLF4^{K409Q} Mutation in Meningioma. *World Neurosurg.* 2021 Oct;154:e665-e670. doi: 10.1016/j.wneu.2021.07.119