

Ukr Neurosurg J. 2022;28(3):52-56  
doi: 10.25305/unj.257987

## The use of different methods of celiac plexus neurolysis in the treatment of pain syndrome associated with pancreatic cancer

Dmytro M. Romanukha<sup>3</sup>, Andrii M. Strokan<sup>2</sup>, Vadym V. Biloshytsky<sup>1</sup>

<sup>1</sup> Romodanov Neurosurgery Institute, Kyiv, Ukraine

<sup>2</sup> Clinical Hospital «Feofaniya» of the State Administration, Kyiv, Ukraine

<sup>3</sup> Department of Neurosurgery, State Institution «Main Medical Center of the Ministry of Internal Affairs of Ukraine», Kyiv, Ukraine

Received: 31 May 2022

Accepted: 19 August 2022

### Address for correspondence:

Dmytro M. Romanukha, Department of Neurosurgery, State Institution «Main Medical Center of the Ministry of Internal Affairs of Ukraine», 1 Berdychivs'ka Street, Kyiv, 04116, Ukraine, e-mail: neuromanukha@gmail.com

The celiac plexus is a recognized target for interventions to provide pain relief to patients with pain resulting from inoperable malignancies of the pancreas or other organs in the upper abdomen.

The clinical case of a 66-year-old female patient with pancreatic cancer who underwent several different techniques of celiac plexus neurolysis to reduce pain is presented. Due to the large size of the tumor and its extension into adjacent organs, it was not possible to perform sympatholysis during the biopsy using endoscopic ultrasonography. An attempt of neurolysis through an anterior transabdominal US-guided approach did not bring the desired result. Posterior percutaneous paravertebral CT-guided approach provided a significant relief of the patient's condition.

Comparisons of different methods of the celiac plexus neurolysis and their advantages and disadvantages of use in health care institutions of Ukraine are given.

If it is impossible to perform neurolysis with the help of endosonography, anterior transabdominal US-guided approach, or if there are difficulties in performing them, we recommend performing neurolysis by posterior percutaneous-paravertebral CT-guided approach.

**Key words:** neurolysis; sympatholysis; celiac plexus; solar plexus; pancreatic cancer; abdominal pain; pain management; endoscopic ultrasound.

Epigastric and back pain due to pancreatic malignancies can be challenging to treat with systemic analgesia. With the increasing number and doses of systemic analgesics, the frequency of side effects of drugs, such as drowsiness, dizziness, constipation, itching, nausea, vomiting, etc., increases [1, 2]. These side effects can further impair quality of life, which is important for this patient cohort, whose five-year survival rate is only 8% [3].

The celiac (solar) plexus (CP) is a recognized target for analgesic interventions. Pain occurs due to an inoperable malignant neoplasm of the pancreas or other organs located in the upper half of the abdominal cavity [4].

There are several methods of neurolysis (sympatholysis) of CP:

1. Anterior percutaneous transabdominal approach [5]. Performed using ultrasonic navigation. Puncture through the anterior abdominal wall, anterior and posterior walls of the stomach. This approach can also be performed using computed tomography (CT) or magnetic resonance imaging (MRI).

2. Bilateral or unilateral posterior percutaneous paravertebral approach [6, 7]. One of the most common approaches in practice. It is performed under fluoroscopic, CT or MRI control.

3. Intraoperative approach [8]. Neurolysis is performed directly during surgery, which is not always possible, for example, in the case of a large tumor size or surrounding structures invasion together with the CP area.

4. Endoscopic-ultrasonic (endosonographic, endoscopic ultrasonography) approach [9]. It is also one of the most common techniques. It is performed according to the method of endoscopic examination of the stomach, a puncture through its posterior wall using ultrasonic guidance (with the help of a transducer located at the distal end of the endoscope), which allows visualization of the adjacent organs.

### Clinical case

A 66-year-old patient, who had not been treated before, and during the last two weeks she felt constant intractable pain in the upper part of the abdomen. She complained of weight loss.

She was admitted to Feofaniya Clinical Hospital. CT and MRI of abdominal organs with contrast were performed. A space-occupying lesion in the body of pancreas and a metastatic mass in the liver were detected. Endoscopic ultrasonography (EUSG) with biopsy of the pancreatic neoplasm through the posterior wall of the stomach was performed (**Fig. 1 and 2**).

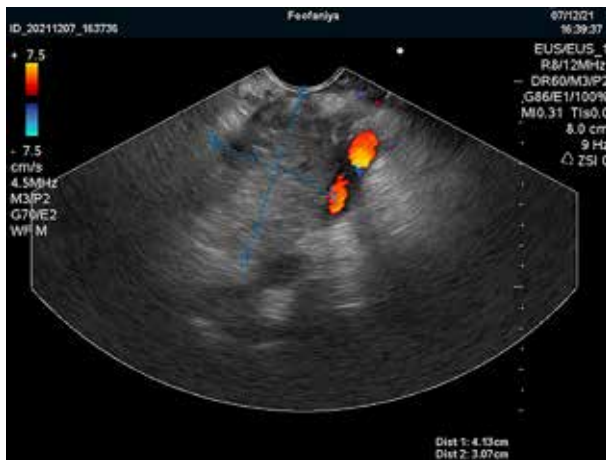
Copyright © 2022 Dmytro M. Romanukha, Andrii M. Strokan, Vadym V. Biloshytsky



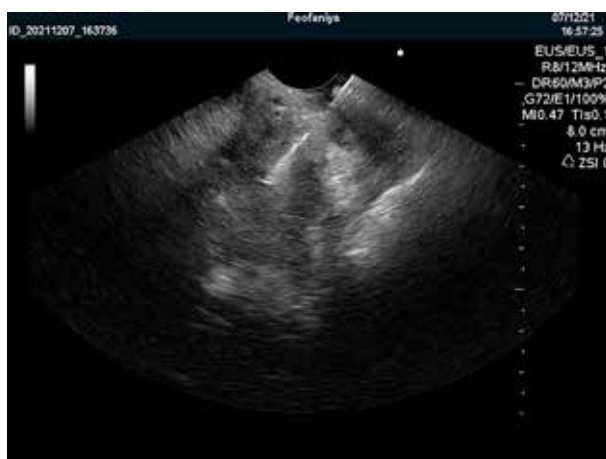This work is licensed under a Creative Commons Attribution 4.0 International License  
<https://creativecommons.org/licenses/by/4.0/>

Pentax device (Japan) with Hitachi (Japan) ultrasonic transducer located at the distal end of the endoscope was used for the examination. Histologically confirmed G2 moderately differentiated ductal adenocarcinoma. Usually, after EUSG-biopsy, neurolysis of the CP is performed, but in this case, the large size of the tumor, its invasion into adjacent organs and CP did not make it possible to perform neurolysis with the help of EUSG.

The patient was diagnosed with pancreatic cancer T<sub>3</sub>N<sub>1</sub>M<sub>1</sub> with metastatic liver disease. The oncological board determined the polychemotherapy regimen. To alleviate the pain syndrome, CP neurolysis was



**Fig. 1.** Endoscopic ultrasonography. One of the scans of the pancreatic tumor, the splenic vein is visible on the right, to which the tumor with an uneven vessel contour is closely adjacent, indicating invasion. The tumor has an uneven parenchyma, mostly hypoechoic with separate hyperechoic loci and anechoic tubular structures, which are probably the remains of partial ducts



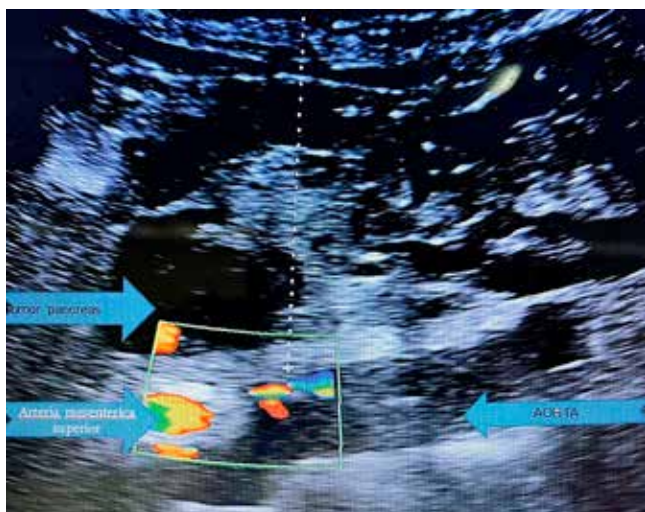
**Fig. 2.** Endoscopic ultrasonography. One of the stages of fine needle biopsy. The white oblique line in the center above is the biopsy needle passing into the tumor mass. There is practically no border between the tumor and the stomach wall, which may indicate invasion into the stomach wall

recommended, but the patient refused treatment or interventions, was seen by an oncologist, and took non-steroidal anti-inflammatory drugs and narcotic analgesics for pain relief. The patient did not tolerate narcotic drugs well, in particular nalbuphine. Three months after diagnosis, the pain was so excruciating (10 cm on the visual analog scale (VAS)) that it forced the patient to seek medical care again.

It was decided to perform CP sympatholysis by anterior percutaneous transabdominal approach with US-guided puncture of anterior and posterior walls of the stomach. Intravenous sedation was performed for this procedure, the patient was in a supine position. GE Healthcare (USA) ultrasound device with Doppler sonography was used for navigation, in order to prevent damage to large arterial vessels (aorta, celiac trunk with branches), around which CP nodes are located. However, it was not possible to fully perform neurolysis. When the anesthetic (bupivacaine 0.5%) was injected, its uneven distribution was revealed (**Fig. 3**), rather laterally from the CP projection, possibly caused by altered anatomy of this area and large tumor size, which did not allow the anesthetic to be evenly distributed antecrurally around the celiac trunk (localization of CP nodes). Therefore, alcohol was not administered to prevent possible complications and untargeted and uncontrolled spread of ethanol in the abdominal cavity. 4 hours after the procedure, the pain score according to VAS did not change significantly - 8 cm.

In view of the persistence of pain syndrome, it was decided to perform sympatholysis of the CP by posterior paravertebral antecrural CT-guided approach (Aquilion ONE GENESIS (Canon) 640-slice device, Japan). The procedure was performed on an empty stomach; 500 ml of saline was administered intravenously before the procedure. The patient's position was in prone position; standard ASA vital signs monitoring systems were connected to the computer tomography scanner table. Intravenous anesthesia was performed. Under sterile conditions, after marking the injection sites and local infiltration with 1% lidocaine at the Th12-L1 level, a 22G 120 mm needle was inserted on the right, reaching the antecrural space (**Fig. 4**). The position of the needle in the fibers of the CP was confirmed using 2 ml of diluted Triombrast 60 contrast (Farmak, Ukraine). Free diffusion of contrast in the antecrural space was observed during computed tomography scanning. First, 10 ml of 0.5% bupivacaine was injected, followed slowly by 20 ml of 70% ethanol. According to control CT scan, the neurolytic agent spread along the anterolateral surface and anterior to the aorta in the retroperitoneal space. Before pulling out the needles, 3 ml of physiological saline was injected to minimize the risk of spreading the alcohol left in the needle to the soft tissues at the puncture site, which prevents local burning pain at the injection site. A computed tomography scan demonstrated a mixture of contrast, air, and ethanol surrounding the lateral and anterior surface of the aorta in the area of the celiac trunk origin (**Fig. 5**).

After the procedure, the pain assessment according to VAS was 4 cm. There is no need for additional pain



**Fig. 3.** Ultrasound Doppler navigation during neurolysis. The tumor and large arteries are marked. Uneven spread of anesthetic laterally from the celiac plexus projection (not represented in this projection)

management during the rest of life (6 weeks). An increase in the level of total bilirubin in the biochemical blood test was noted. This indicator normalized within one week. Transient diarrhea resolved within a couple of days.

According to the literature, endoscopic-ultrasonic and posterior percutaneous-paravertebral CT-guided approach are the most common [4–9].

It is believed that CP endosonographic-guided block is considered to be accompanied by a lower complication rate than percutaneous approaches, thus avoiding damage to nervous structures. The distance between the puncture site and the plexus is shorter [10]. In the study by F. Gress *et al.*, in which CT and EUSG-guided CP blocks were compared, it was found that EUSG-guided blocks were more effective, provided more sustainable pain relief, and were more affordable for patients compared to blocks which are CT-guided [11].

The advantages of the EUSG-approach are the precise orientation of the needle above or to the side of the celiac trunk and the performance of the real-time procedure using Doppler monitoring of surrounding vessels. It is possible to control the diffusion of a neurolytic agent without the use of contrast agents. In addition, this technique can be used immediately after taking biopsy material of an inoperable pancreatic tumor and requires little time. The EUSG method does not require additional irradiation of the patient and medical staff, unlike using fluoroscopy or CT.

The disadvantages of EUSG include high cost (apparatus and consumables), unclear visualization of extraperitoneal structures (pancreas) and significant dependence of the effectiveness of the technique on the skill and experience of the specialist, as well as the patient's constitution (visualization of patients with hypersthenic constitution and other peculiarities is worse). Since this is an invasive method, there is a risk of complications, for example, gastric perforation, pancreatitis, etc. Accurate identification of CP can be difficult, especially if the neurolytic solution (hyperechoic) interferes with CP visualization. Contraindications to performing EUSG: pronounced narrowing (stricture) of the esophagus or tumor growth of the esophageal wall, which prevents the passage of the apparatus, etc.

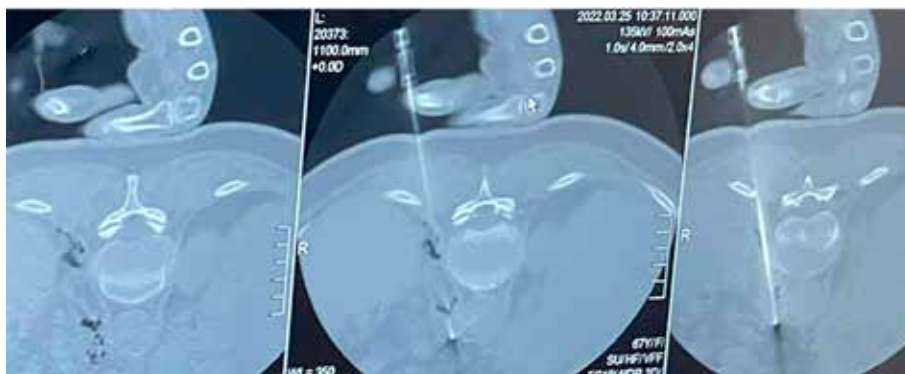Performing EUSG is not always possible. For example, in case of large tumor size, invasion of the surrounding structures, in particular areas of the celiac trunk and celiac plexus, infiltration of the posterior surface of the stomach. This does not make it possible to fully perform sympatholysis with the help of EUSG, which is demonstrated by the example of clinical observation, when it was the percutaneous posterior CT-guided approach that proved to be effective.

M. J. Levy *et al.* point out that endoscopic CP block is a safe alternative and at least as effective as percutaneous approaches, with fewer potential side effects [12].

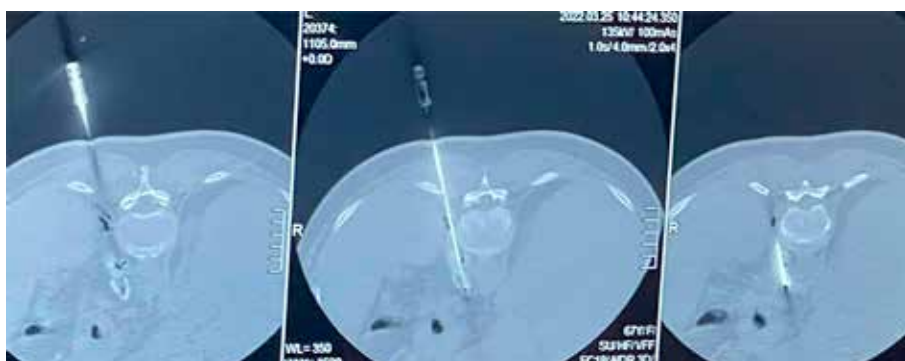Opposite conclusions were obtained in an extensive systematic review involving 66 articles, which compared percutaneous CT-guided techniques with EUSG [13]. The effectiveness of both methods has been established. Specific complications are inherent to both techniques. There is no proven effect of EUSG on reducing opioid use, therefore percutaneous techniques remain the standard of care with a solid evidence base, unlike EUSG.

Computed tomography-guided sympatholysis provides high-quality images with clear differentiation of anatomical structures, such as the pancreas, aorta, celiac trunk, superior mesenteric artery and CP, visualization of the tumor, its spread, the presence of muscle invasion, etc. With the help of CT scan, more accurate planning of the procedure is possible (needle puncture site, depth and angle of its insertion). Focusing on the tip of the needle, you can know exactly where the neurolytic agent is injected, which helps avoid damage to organs and blood vessels. Another advantage is an accurate image of the diffusion of neurolytic agents in the antecrural space.

Disadvantages include risks associated with ionizing radiation. The possibility of neurological complications is <1% [14]. Lower paraparesis or paraplegia occur in 0.15% of cases and may result from spinal cord injury due to a needle puncture, the spread of ethanol into the subarachnoid space, the introduction of a neurolytic agent into the anterior spinal artery or the artery of Adamkiewicz, or damage to them [15]. Other complications are mentioned as occasional cases: retroperitoneal hematoma, pneumothorax,



**Fig. 4.** Sympatholysis using a right-sided posterior paravertebral antecrucial CT-guided approach. Gradual advancement of the needles to the lateral and anterior surface of the aorta at the level of the celiac trunk (Th12–L1 level to the right)



**Fig. 5.** Contrast was injected to confirm the needle position, then 20 ml of 70% ethanol was slowly injected. Free diffusion of the neurolytic agent is visualized antecrucially to the right and in front of the aorta and the celiac trunk - the location of nodes of the celiac plexus

chylothorax, chemical pericarditis, pleuritis or peritonitis, gastroparesis, superior mesenteric vein thrombosis, aortic dissection, aortic pseudoaneurysm, transient hematuria, retroperitoneal abscess or fibrosis, pulmonary embolism, bacteremia [16– 18].

The tumor can also spread behind the pancreas (along the posterior paravertebral approach), affect the musculoskeletal system (paravertebral muscles and ligaments) or abdominal cavity walls. This should also be taken into account. Before performing the procedure, check out the results of CT and MRI examination of the patient. Treatment of somatic pain caused by damage to, for example, paravertebral muscles, is most likely to be ineffective since somatic pain fibers from these structures do not pass through the CP [16].

With the help of MRI, all soft tissues and organs are well visualized, while there is no impact of ionizing radiation on the patient and medical staff, as well as the need to use contrast agents [19]. Limitations of the method: high cost, longer procedure duration, contraindications to MRI (presence of metal implants, cardiac pacemakers, fragmented metal debris, etc.).

Sympatholysis is usually most cost-effective under ultrasonic or fluoroscopic guidance. Many hospitals in Ukraine have an ultrasound device with Doppler or C-arm, the cost of which does not exceed the purchase and installation of CT or MRI. These are cost-effective

and simple procedures. However, fluoroscopic-guided neurolysis is used less and less in clinical practice, which is associated with the lack of visualization and differentiation of both CP, neighboring internal organs (pancreas, kidneys, etc.), and vessels, even of large caliber [7, 20]. This increases the risk of possible complications. Not always clear visualization of extraperitoneal structures (pancreas), significant dependence of technique effectiveness on the skill and experience of a specialist, as well as patient's hypersthenic constitution give reason to consider ultrasound-guided sympathectomy as the method of choice [21].

Purchase and installation of CT or MRI machine in a medical institution usually exceeds the cost of purchasing equipment for endosonography. However, the EUSG device includes two important elements: an endoscope and an ultrasound device with a transducer. There are two modifications on the market: Olympus EUSG device and Pentax endoscope with Hitachi ultrasound equipment. The cost of new medical equipment together with the rack is UAH 15-20 million. Therefore, we believe that it is economically more expedient in hospitals where there is a CT machine to give preference to percutaneous methods of CP neurolysis under CT -guidance.



## Conclusions

1. Celiac plexus neurolysis is a safe, minimally invasive and effective procedure that can be used to reduce pain associated with pancreatic cancer.

2. In case of impossibility of performing neurolysis using endosonography by anterior transabdominal approach under ultrasound navigation, or in case of difficulties during their performance, we recommend performing neurolysis by posterior percutaneous-paravertebral CT – guided approach.

## Disclosure

### Conflict of Interest

There is no potential conflict of interest relevant to this case report.

### Patient Consent

This study obtained patient consent directly from the patient.

## References

- Zacharias NA, Karri J, Garcia C, Lachman LK, Abd-Elseyed A. Interventional Radiofrequency Treatment for the Sympathetic Nervous System: A Review Article. *Pain Ther.* 2021 Jun;10(1):115-141. doi: 10.1007/s40122-020-00227-8
- Kurita GP, Sjögren P, Klepstad P, Mercadante S. Interventional Techniques to Management of Cancer-Related Pain: Clinical and Critical Aspects. *Cancers (Basel).* 2019 Mar 29;11(4):443. doi: 10.3390/cancers11040443
- Siegel RL, Miller KD, Jemal A. Cancer Statistics, 2017. *CA Cancer J Clin.* 2017;67(1):7-30. doi: 10.3322/caac.21387
- Dobosz Ł, Kaczor M, Stefaniak TJ. Pain in pancreatic cancer: review of medical and surgical remedies. *ANZ J Surg.* 2016;86(10):756-761. doi: 10.1111/ans.13609
- Bhatnagar S, Joshi S, Rana SP, Mishra S, Garg R, Ahmed SM. Bedside ultrasound-guided celiac plexus neurolysis in upper abdominal cancer patients: a randomized, prospective study for comparison of percutaneous bilateral paramedian vs. unilateral paramedian needle-insertion technique. *Pain Pract.* 2014;14(2):E63-E68. doi: 10.1111/papr.12107
- Shoshiashvili V, Japharidze N, Shoshiashvili I, Rukhadze T. Computed Tomography Guided Transdiscal Splanchnic Nerve Block for Cancer Pain Treatment. *J Anesth Clin Res.* 2020;11:964. doi: 10.35248/2155-6148.20.11.964
- Eroshkin AA, Romanukha DM. CT-Guided Celiac Plexus Neurolysis in the Management of Severe Upper Abdominal Pain. *Ukrainian Neurosurgical Journal.* 2020;26(2):34-45. doi: 10.25305/unj.201779
- Masuda T, Kuramoto M, Shimada S, et al. Splanchnicectomy for pancreatic cancer pain. *Biomed Res Int.* 2014;2014:941726. doi: 10.1155/2014/941726
- Asif AA, Walayat SK, Bechtold ML, Revanur V, Puli SR. EUS-guided celiac plexus neurolysis for pain in pancreatic cancer patients - a meta-analysis and systematic review. *J Community Hosp Intern Med Perspect.* 2021;11(4):536-542. Published 2021 Jun 21. doi: 10.1080/20009666.2021.1929049
- Cornman-Homonoff J, Holzwanger DJ, Lee KS, Madoff DC, Li D. Celiac Plexus Block and Neurolysis in the Management of Chronic Upper Abdominal Pain. *Semin Intervent Radiol.* 2017;34(4):376-386. doi: 10.1055/s-0037-1608861
- Gress F, Schmitt C, Sherman S, Ikenberry S, Lehman G. A prospective randomized comparison of endoscopic ultrasound- and computed tomography-guided celiac plexus block for managing chronic pancreatitis pain. *Am J Gastroenterol.* 1999;94(4):900-905. doi: 10.1111/j.1572-0241.1999.01042.x
- Levy MJ, Topazian MD, Wiersema MJ, Clain JE, Rajan E, Wang KK, de la Mora JG, Gleeson FC, Pearson RK, Pelaez MC, Petersen BT, Vege SS, Chari ST. Initial evaluation of the efficacy and safety of endoscopic ultrasound-guided direct ganglia neurolysis and block. *Am J Gastroenterol.* 2008 Jan;103(1):98-103. doi: 10.1111/j.1572-0241.2007.01607.x
- Nagels W, Pease N, Bekkering G, Cools F, Dobbels P. Celiac plexus neurolysis for abdominal cancer pain: a systematic review. *Pain Med.* 2013 Aug;14(8):1140-63. doi: 10.1111/pme.12176
- Titton RL, Lucey BC, Gervais DA, Boland GW, Mueller PR. Celiac plexus block: a palliative tool underused by radiologists. *AJR Am J Roentgenol.* 2002 Sep;179(3):633-6. doi: 10.2214/ajr.179.3.1790633
- Davies DD. Incidence of major complications of neurolytic coeliac plexus block. *J R Soc Med.* 1993 May;86(5):264-6.
- Kambadakone A, Thabet A, Gervais DA, Mueller PR, Arellano RS. CT-guided celiac plexus neurolysis: a review of anatomy, indications, technique, and tips for successful treatment. *Radiographics.* 2011 Oct;31(6):1599-621. doi: 10.1148/rg.316115526
- McAninch SA, Raizada MS, Kelly SM. Pulmonary embolism following celiac plexus block and neurolysis. *Proc (Bayl Univ Med Cent).* 2016 Jul;29(3):329-30. doi: 10.1080/08998280.2016.11929458
- Dumitrescu A, Aggarwal A, Chye R. A retrospective case series of patients who have undergone coeliac plexus blocks for the purpose of alleviating pain due to intra-abdominal malignancy. *Cancer Rep (Hoboken).* 2020;3(5):e1265. doi: 10.1002/cnr2.1265
- Jin G, Qiu X, Ding M, Dai M, Zhang X. Navigated magnetic resonance imaging-guided celiac plexus neurolysis using an open magnetic resonance system for pancreatic cancer patients with upper abdominal pain. *J Cancer Res Ther.* 2019;15(4):825-830. doi: 10.4103/jcrt.JCRT\_38\_19
- Choi EJ, Choi YM, Jang EJ, Kim JY, Kim TK, Kim KH. Neural Ablation and Regeneration in Pain Practice. *Korean J Pain.* 2016 Jan;29(1):3-11. doi: 10.3344/kjp.2016.29.1.3
- Wyse JM, Chen YI, Sahai AV. Celiac plexus neurolysis in the management of unresectable pancreatic cancer: when and how? *World J Gastroenterol.* 2014 Mar 7;20(9):2186-92. doi: 10.3748/wjg.v20.i9.2186