

Ukr Neurosurg J. 2022;28(2):54-56
doi: 10.25305/unj.257985

Mine blast injury of the spine and spinal cord: a case report

Ievgenii I. Slyenko, Yurii V. Derkach, Arthur I. Ermolev, Oleksii S. Nekhlopochny, David A. Tevzadze

Spinal Department, Romodanov
Neurosurgery Institute, Kyiv, Ukraine

Received: 01 May 2022
Accepted: 25 May 2022

Address for correspondence:

Yurii V. Derkach, Spinal Department,
Romodanov Neurosurgery Institute,
32 Platona Maiborody st., Kyiv,
04050, Ukraine, e-mail: 290986@
ukr.net

Many soldiers who were wounded during the war in Ukraine with Russia increased the number of cases of spinal injury.

As a result of the Russia-Ukraine war, the number of patients with spine and spinal cord injuries increased significantly.

According to the literature, gunshot wounds to the spine and spinal cord accounted for 0.26% of all soldier injuries during the American Civil War, with a mortality rate of 55%. According to the U.S. military data, spinal and spinal cord injuries accounted for 1.2% of war-related deaths during the Korean War, 1.0% - during the Vietnam War and the Gulf War, 6.0% - during the US invasion of Panama, 11.1% - during the war in Afghanistan and Iraq. Disability related to spinal cord injuries (14.0%) is currently the leading cause of discharge from military service for U.S. soldiers who have been injured.

Patient M., 32 years old, male sustained mine blast injury. Immediately after the injury there was tetraplegia.

Surgery was performed to correct vertebrae C7–Th1, decompression of the spinal cord at the level of vertebrae C7–Th1. Sixteen days after surgery, the neurological deficit regressed to the Frankel C clinical group. The patient was transferred to rehabilitation treatment.

A clear, consistent, rapid algorithm of action in spinal cord injuries allowed to provide highly qualified care, which allowed to achieve significant results in the regression of neurological deficits in the postoperative period.

Key words: mine blast injury; spinal cord injury; cervical spine injury.

As a result of the Russia-Ukraine war, the number of patients with spine and spinal cord injuries increased significantly.

According to the literature, gunshot wounds to the spine and spinal cord accounted for 0.26% of all soldier injuries during the American Civil War, with a mortality rate of 55% [1]. According to the U.S. military data [2], spinal and spinal cord injuries accounted for 1.2% of war-related deaths during the Korean War, 1.0% - during the Vietnam War and the Gulf War, 6.0% - during the US invasion of Panama, 11.1% - during the war in Afghanistan and Iraq. Disability related to spinal cord injuries (14.0%) is currently the leading cause of discharge from military service for U.S. soldiers who have been injured [3].

Clinical case

Patient M., 32 years old, male sustained a mine blast injury. Immediately after the injury, according to the patient and according to medical records, there were no movements in the lower extremities and hands. Primary care was provided at the prehospital stage.

The patient was taken to a local hospital. The study was performed according to the polytrauma protocol (X-ray of the chest, limbs, pelvis, computed tomography of the brain, spine, chest organs, magnetic resonance imaging of the cervical spine) (**Fig. 1, 2**).

The diagnosis was made: mine blast injury. Polytrauma. Severe contusion of the spinal cord and spine. Fracture-dislocation at the level of C7–Th1 vertebrae with traumatic absolute stenosis of the spinal canal at the level of C7–Th1 vertebrae. Contusion of the spinal cord at the level of C7–Th1 vertebrae. Lower paraplegia. Upper paraparesis. Clinical group Frankel A. Closed craniocerebral injury. Cerebral contusion with the formation of contusion foci in the temporal region on the right. Closed chest injury. Hemothorax on both sides. Contusion of both lungs.

The patient was consulted by a thoracic surgeon, a surgeon, a traumatologist, and a neurosurgeon in absentia. Given the presence of osteo-traumatic changes in the cervical spine, pronounced neurological deficit corresponding to the level of damage, it was decided to transport the patient to the Institute of Neurosurgery named after Acad. A.P. Romodanov.

It was decided to perform a surgical intervention in the amount of corpectomy of the C7–Th1 vertebrae and decompression of the spinal cord at the level of the C7–Th1 vertebrae, corporedesis using a titanium interbody implant at the level of the C7–Th1 vertebrae (**Fig. 3**). The surgical intervention was performed according to the generally accepted technique for spinal and spinal cord injuries. There were no complications during



surgery. After surgery, the patient was transferred to the resuscitation and intensive care unit. The day after surgery, a control study with the help of spiral computed tomography was performed (**Fig. 4**).

In the early postoperative period, the volume of movements in the hands and left lower extremity increased, sensitivity appeared in the right lower extremity.

The patient received conservative therapy (antibacterial, anti-edematous, restorative), underwent a course of treatment with a physiotherapist.

By the time of discharge (16 days after surgery), the neurological deficit had regressed to a Frankel grade C.

The patient was discharged in a satisfactory condition for further rehabilitation therapy.

Conclusions

In the given clinical case, the patient's whole pathway from injury to discharge after surgical intervention was analyzed. Positive dynamics in the postoperative period depended on many factors (evacuation of the patient, time, coordinated and qualified work at all stages of the

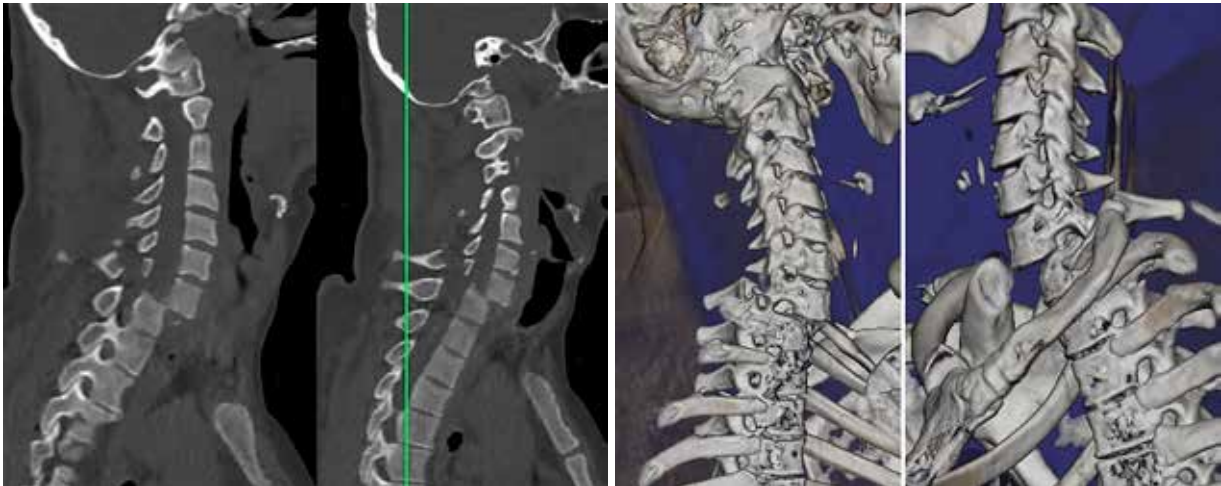


Fig. 1. Spiral computed tomography of the cervical spine before surgery

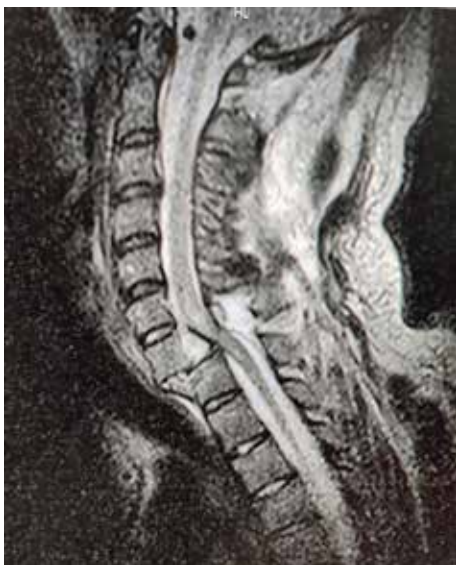

Fig. 2. Magnetic resonance imaging of the cervical spine before surgery

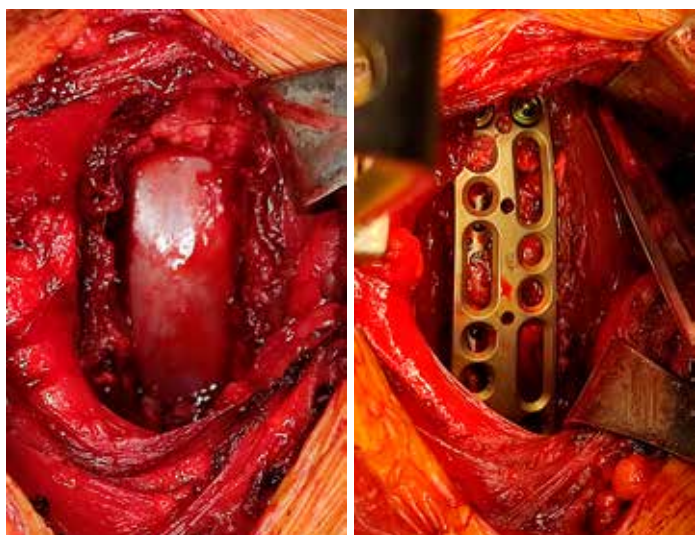


Fig. 3. Intraoperative photo

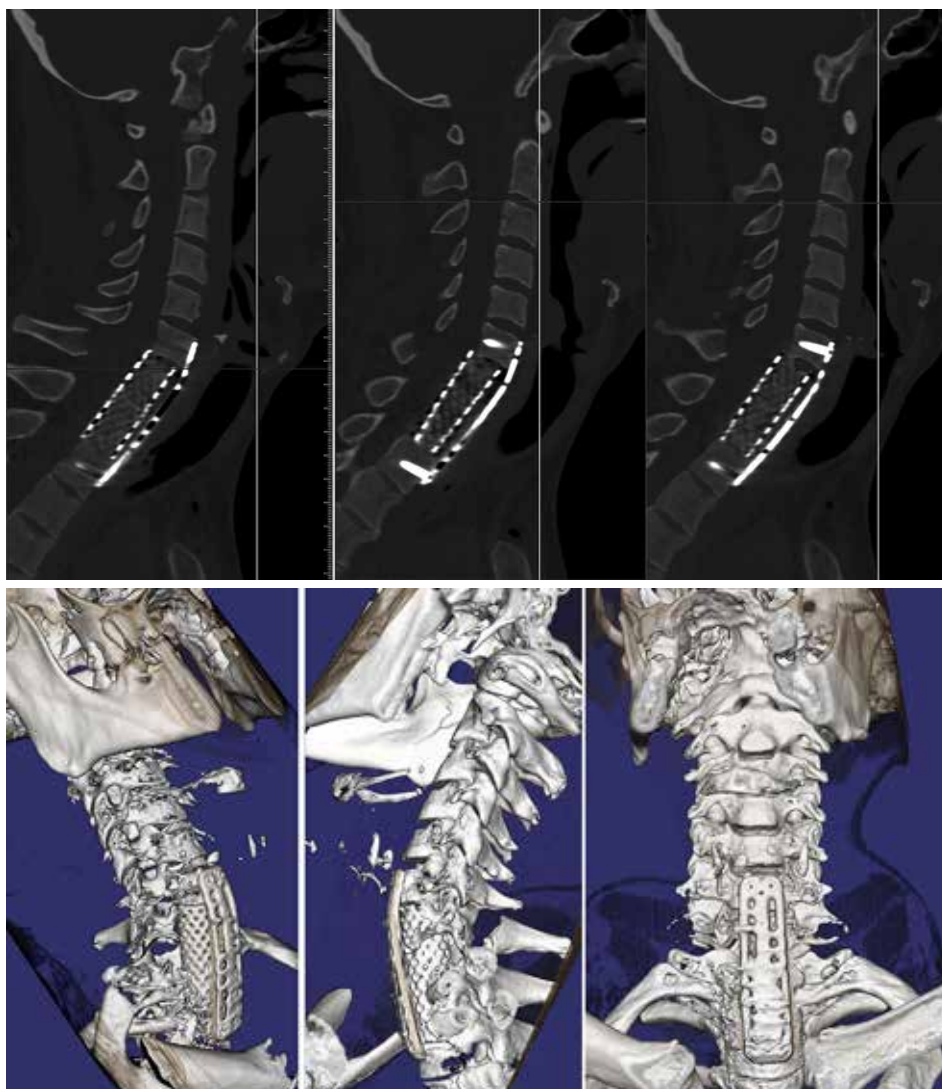


Fig. 4. Spiral computed tomography of the cervical spine after surgery

patient's treatment), which significantly improved the treatment outcome.

A clear, consistent and rapid algorithm of actions in case of injury to the spine and spinal cord made it possible to provide highly qualified care, which contributed to a significant regression of the neurological deficit in the postoperative period.

Disclosure

The authors declare no conflict of interest regarding the materials or methods used in this study as well as conclusions presented in this paper.

Patient Consent

This study obtained patient consent directly from the patient.

References

1. Furlan JC, Gulasingam S, Craven BC. Epidemiology of War-Related Spinal Cord Injury Among Combatants: A Systematic Review. *Global Spine J.* 2019 Aug;9(5):545-558. doi: 10.1177/2192568218776914.
2. Furlan JC, Gulasingam S, Craven BC. The Health Economics of the spinal cord injury or disease among veterans of war: A systematic review. *J Spinal Cord Med.* 2017 Nov;40(6):649-664. doi: 10.1080/10790268.2017.1368267.
3. Blackbourne LH, Baer DG, Eastridge BJ, Kheirabadi B, Bagley S, Kragh JF Jr, Cap AP, Dubick MA, Morrison JJ, Midwinter MJ, Butler FK, Kotwal RS, Holcomb JB. Military medical revolution: prehospital combat casualty care. *J Trauma Acute Care Surg.* 2012 Dec;73(6 Suppl 5):S372-7. doi: 10.1097/TA.0b013e3182755662. Erratum in: *J Trauma Acute Care Surg.* 2013 Feb;74(2):705. Kotwal, Russell S [corrected to Kotwal, Russ S]. Erratum in: *J Trauma Acute Care Surg.* 2013 Jan;74(1):347. Bagley, Stephanie [added]. PMID: 23192058.