

Ukr Neurosurg J. 2021;27(4):23-29  
doi: 10.25305/unj.240739

## Surgical treatment of glossopharyngeal nerve schwannomas: Results of two-center study (14 patients included) and literature review

Andrii H. Sirko<sup>1,2</sup>, Oleksandr M. Lisiany<sup>3</sup>, Oksana Y. Skobska<sup>4</sup>, Rostislav R. Malyi<sup>2</sup>, Iryna O. Popovych<sup>4</sup>, Oksana V. Zemskova<sup>5</sup>

<sup>1</sup> Neurosurgery Department N2, Mechnikov Dnipropetrovsk Regional Clinical Hospital, Dnipro, Ukraine

<sup>2</sup> Neurology and Neurosurgery Department, Postgraduate Education Faculty, Dnipropetrovsk State Medical University, Dnipro, Ukraine

<sup>3</sup> Department of Subtentorial Tumors, Romodanov Neurosurgery Institute, Kyiv, Ukraine

<sup>4</sup> Group of Otoneurology, Romodanov Neurosurgery Institute, Kyiv, Ukraine

<sup>5</sup> Department of Neurosurgery, Romodanov Neurosurgery Institute, Kyiv, Ukraine

Received: 14 September 2021

Accepted: 11 November 2021

### Address for correspondence:

Andrii H. Sirko, Cerebral Neurosurgery Department No. 2, Mechnikov Dnipropetrovsk Regional Clinical Hospital, 14 Soborna Square, Dnipro, 49005, Ukraine, e-mail: [neurosirko75@gmail.com](mailto:neurosirko75@gmail.com)

**Objective:** This study is aimed to analyze the outcomes of surgical treatment of glossopharyngeal schwannomas based on pre- and postoperative neurological status assessment.

**Materials and methods:** This paper is a retrospective analysis of examination and surgical treatment of 14 patients who were operated on in two large clinics from 2018 to 2021 inclusive. When analyzing the collected data, gender, age, disease symptoms, tumor size and location, surgical approach, tumor to cranial nerves (CN) ratio, jugular foramen (JF) condition, and tumor removal volume were taken into account. All tumors were divided into groups depending on tumor location relative to the JF. Particular attention was paid to assessing cranial nerves functions. Facial nerve function was assessed as per House-Brackmann Scale (HBS), hearing function as per Gardner-Robertson Scale (GRS).

**Results:** 3 (21.4%) patients had total tumor removal: 2 patients had type A tumors and one had type B tumor. Subtotal resection took place in 7 (50%) cases. In 4 cases, a tumor was partially removed: 3 patients had type D tumors and one had type B tumor.

3 (21.4%) patients had preoperative FN deficit (HBS Grade II) and mild dysfunction. 5 (35.7%) patients had postoperative facial nerve deficit: HBS II, 2; III, 1; V, 2.

Preoperative sensorineural type hearing impairment on the affected side was diagnosed in 13 (92.6%) patients. Before surgery, 6 patients had non-serviceable hearing, which remained at the same level after surgery. None of the patients with grade I or II hearing before surgery had any hearing impairment postoperatively. In 2 (14.3%) cases, hearing improved from grade V to grade III after surgery.

6 (42.9%) patients developed new neurological deficit in the caudal group CN. Postoperative deficit of the caudal group CN occurred in type D tumors in 3 patients, type A tumors 2 patients, and type B tumors one patient.

**Conclusions:** Applying a retrosigmoid approach only makes it possible to achieve total tumor removal in case of type A tumors. To remove other tumor types, it is necessary to select approaches that enable access to the jugular foramen and infratemporal fossa. Intraoperative neurophysiological monitoring is an extremely important tool in glossopharyngeal schwannoma surgery.

The most common postoperative complication is a developed or increased deficit of the caudal CN group, which can lead to persistent impairments in the patients' quality of life. Preservation of the CN VII and VIII function in most cases is a feasible task and shall be ensured as a standard for this pathology.

**Key words:** cerebellopontine angle; jugular foramen; non-vestibular schwannoma; glossopharyngeal schwannoma; caudal cranial nerves group schwannoma; diagnosis; clinical picture; cranial nerves

### Introduction

Jugular foramen (JF) schwannomas are rarely diagnosed, their occurrence is 2.9%–4.0% of all intracranial schwannomas. These tumors most often originate from the glossopharyngeal, vagus, and accessory cranial nerves (CN). [1]. This pathology is located in a rather complex and hard-to-reach anatomical structure — the JF, which contains a lot of neurovascular structures, such as: jugular vein, inferior petrosal sinus,

cochlear tubule vein, glossopharyngeal, vagus, and accessory CN. Consequently, surgical removal of such tumor is associated with a high risk of postoperative neurological deficit. The tumors often have a well-developed blood supply, which also affects the complexity of their surgery. Determination of surgical approach depends on preoperative differential tumor diagnosis. Glomus jugulare tumors, caudal CN group schwannomas, and meningiomas account for 80% of tumors of this



location. 10% to 30% of them are schwannomas. [2]. This study is a retrospective analysis of outcomes of surgical treatment of 14 glossopharyngeal nerve schwannoma (GNS) patients, carried out in two clinics (medical care level 3: specialized high-tech neurosurgical care).

### Study objective

This study is aimed to analyze the outcomes of surgical treatment of glossopharyngeal schwannomas based on pre- and postoperative neurological status assessment.

### Materials and methods

#### Study participants

249 medical histories coded D33.3 (benign cranial nerve neoplasms), ICD-10 (WHO, 2007) were analyzed for patients who were examined and treated in 2018 to 2021 at the Subtentorial Neurosurgery Department, Romodanov Neurosurgery Institute, and the Department of Neurosurgery No. 2, Municipal Enterprise, Mechnikov Dnipropetrovsk Regional Clinical Hospital, Dnipropetrovsk Regional Council.

The study is a retrospective analysis of the results of examination and surgical treatment of 14 patients who met the study inclusion criteria. 8 patients were operated in the Romodanov Neurosurgery Institute, 6 in Mechnikov Hospital. GNS accounted for 5.6% of all CN schwannomas in the surgical patients series. Additionally, online English-language literature on the topic over the past 10 years (2010 to 2020) was analyzed using the following keywords: JF tumors, caudal CN group schwannomas, non-vestibular schwannomas, jugular foramen schwannomas, glossopharyngeal schwannomas, surgical treatment.

#### Study inclusion criteria

Study inclusion criteria were as follows: age over 18, unilateral primary GNS, availability of preoperative MRI with intravenous paramagnetic contrast enhancement, histological diagnosis verification.

Exclusion criteria were as follows: age under 18, patients with other CNs schwannomas, including type II neurofibromatosis due to the peculiarities of etiopathogenesis and clinical symptom complex, no MRI with intravenous paramagnetic contrast enhancement, no histological verification.

#### Group characteristics

Depending on the tumor size, tumors were broken down as follows: 11–20 mm = medium, 21–30 mm = moderately large, 31–40 mm = large, 40+ mm = giant

schwannomas. The longest linear tumor size defined tumor assignment to particular group.

All tumors were split into groups according to the classification in **Table 1** [3].

#### Study design

All patients underwent a comprehensive study, which included detailed neurological and otoneurological examinations. In the analysis gender, age, disease symptoms, tumor size and location, surgical approach, tumor to CN ratio, and JF condition were taken into account. Particular attention was paid to assessing cranial nerves functions. Facial nerve function was assessed as per House-Brackmann Scale (HBS), hearing function as per Gardner-Robertson Scale (GRS). All patients underwent 1.5 Tesla brain MRI in T1, T2, Flair, DWI, and AX 3D SSFP IAC modes with intravenous paramagnetic enhancement; brain CT, including bone window; CT angiography using a special software including 3D modeling. Anatomical and topographic tumors characteristics, their spread into internal auditory canal, JF, extracranial spread, brainstem shift, fourth ventricle compression, and presence of hydrocephalus were assessed based on the studies performed and according to the data obtained intraoperatively.

All patients underwent surgical treatment. When removing the tumor, CN function was subjected to intraoperative neurophysiological monitoring with ISIS IOHM, Inomed, Germany, and NIM Response 3.0, Medtronic, USA. The monopolar electrode nerves stimulation through the perineural tumor tissue and/or direct nerves stimulation was applied for the monitoring purposes. A four-channel mode was used to stimulate the facial nerve. To monitor the glossopharyngeal nerve, an electrode was placed in the palatine arch. For direct stimulation, a current starting from 1.0 mA with gradual decrease to 0.05 mA was applied, with event recording threshold of 100  $\mu$ V. In case of initial deficit or in elderly patients: initial stimulation current was 1.2–1.5 mA and event registration threshold was 80–90  $\mu$ V. The monitoring (a free-running EMG) was also performed given the spontaneous nerves activity.

The following relative criteria were used to assess tumor removal degree: total (removal of more than 95% of the tumor), subtotal (removal of 80–94% of the tumor), partial (removal of 50–79% of the tumor), biopsy (removal of less than 50% of the tumor).

Postoperative results were assessed using neurological and otoneurological examinations, CT and MRI with

**Table 1.** Jugular foramen schwannomas classification [3].

Type	Definition
A	Tumor originating from the cisternal part of the nerves without significant spread to the JF
B1 B2 B3	Intraosseous tumor inside the jugular foramen Intraosseous tumor with predominant spread to the cisternal space Intraosseous tumor with predominant spread to the infratemporal fossa
C	Tumor originating from the peripheral part of the nerve (extracranial)
D	Triple dumbbell-shaped tumor with intracranial, intraosseous, and extracranial parts

*This article contains some figures that are displayed in color online but in black and white in the print edition*

intravenous enhancement. Particular attention was paid to assessing CN dysfunction before and after the surgery.

#### Statistical analysis

The data was processed and analyzed using STATISTICA 10 (StatSoft® Inc., USA, license No. STA862D175437Q) and SPSS 17.0 (IBM, USA). Differences were considered statistically significant at  $p < 0.05$ .

Written informed consent was obtained from all patients to conduct the study, in accordance with the World Medical Association's Declaration of Helsinki — Ethical Principles for Medical Research Involving Human Subjects (1964–2008), Directive 86/609/EEC on humans participation in biomedical research, and the Order of the Ministry of Healthcare of Ukraine, as amended, No. 690 dd 23.09.2009.

### Results and discussion

In the presented group of patients, women predominated — 9 (64.3%) patients. The average patient age was 46.4 [33.5; 66.5]. The men's age was 44.8 [35; 59]. vs. 50.8 [32; 61]. in women. The difference between the average age of men and women was not statistically significant ( $p = 0.17$ ). No lateralization of the tumor process was observed: in 8 patients, the tumor was located on the right; in 6, on the left ( $p = 0.27$ ).

The peculiarity of the clinical picture was that the most frequent symptoms on admission were hearing loss in 13 (92.9%) patients, tinnitus in 12 (85.7%) patients, and unsteady gait in 10 (71.4%) patients (**Fig. 1**).

In all cases, the cisternal tumor part was mostly located in the cerebellopontine angle; CNs VII and VIII were stretched over the upper tumor pole, and caudal CN group under the lower pole. In 10 (71.4%) cases, the tumor spread to the JF and expanded its lumen. 12 (85.7%) patients had significant brainstem, cerebellar hemisphere, and the fourth ventricle compression. In 10 (71.4%) cases, the tumor included cystic cavities of different diameters. In 2 of 14 patients, most of the tumor was an extensive necrosis area. In 2 (14.3%) patients, the tumor caused destruction of both jugular foramen and internal auditory canal with CN VII–VIII involved in the pathological process.

After a detailed analysis of clinical and neuroimaging studies and intraoperative data, the initial tumor growth

from the glossopharyngeal nerve was diagnosed in all cases.

According to the above classification (**Table 1**) depending on tumor location and spread, tumors were broken down as follows: type A, 6 (42.9%) patients; type B, 2 (14.3%) patients, type D, 6 (42.9%) patients, type C not diagnosed.

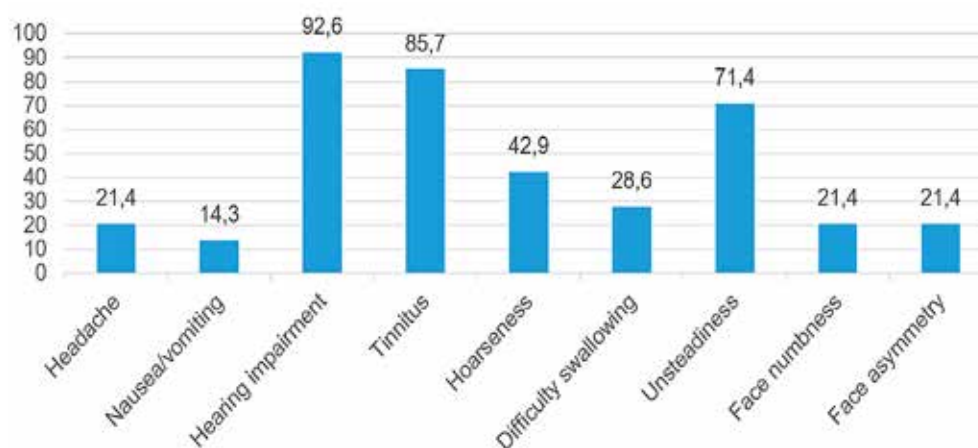
Linear tumor sizes ranged from 25 to 54 mm (**Table 2**). Moderately large schwannomas were found in 2 (14.3%) patients, large in 5 (35.7%) patients, giant in 7 (50%) patients. Thus, large and giant tumors dominated in the study (85.7% of cases). The tumors had a pronounced growth in all directions with a tendency towards predominant growth in the rostro-caudal direction. Thus, the average mediolateral tumor size was  $33.6 \pm 1.8$  mm, anteroposterior was  $35.6 \pm 3.3$  mm, rostrocaudal was  $36.3 \pm 2.3$  mm.

In most cases (11 (78.6%)), the tumor was removed using the standard retrosigmoid approach. In 3 (21.4%) cases, an extended retrosigmoid approach was applied with resection of the foramen magnum semicircle and the C1 vertebral arch. Extended approaches were applied in type A (2 patients) and type D (1 patient) tumors. In one case (type D tumor), a retrosigmoid approach using endoscopic assistance was used, which helped completely remove the intraforaminal part of the tumor.

3 (21.4%) patients had total tumor removal: 2 patients had type A tumors and one had type B tumor. Subtotal resection took place in 7 (50%) cases. In 4 cases, a tumor was partially removed: 3 patients had type D tumors and one had type B tumor.

3 patients underwent repeated GNS surgery. In the first case, repeated (2 years later) removal was performed due to the continued growth of previously partially removed tumor. In the second case, the tumor was removed again (2 months later) after the first unsuccessful removal attempt in another center. In the third case, the intracranial part of the tumor was removed by retrosigmoid approach after the first treatment stage — removal of the extracranial part of the tumor by transcervical approach in another clinic. The interval between the first and the second surgery was 5 months.

5 (35.7%) patients had preoperative occlusive hydrocephalus. One patient with decompensated



**Fig. 1.** Clinical symptoms on admission

hydrocephalus had ventriculoperitoneal shunt inserted; the tumor removal surgery itself was performed 2 weeks after hydrocephalus regression and patient's condition improvement. In another case, in order to prevent hydrocephalus growth during tumor removal, the first stage was ventriculocisternal shunting as per Torkildsen and craniovertebral junction decompression. In 3 other cases, one tumor removal was sufficient for regression of the hydrocephalus that existed before the surgery.

After tumor removal, hydrocephalus developed in 2 patients at different times post surgery. In one case, acute occlusive hydrocephalus developed on the first day after the surgery, which required insertion of external ventricular drain. External drainage lasted 4 days; after ventricular drain was removed, there was no need for

other CSF shunting surgeries. In another case, 3 weeks after total tumor removal, non-occlusive non-resorptive hydrocephalus developed, which required installation of a low pressure ventriculoperitoneal shunt.

**Table 2** presents clinical characteristics of findings with an emphasis on tumor resection completeness and assessment of changes in the cerebellopontine angle CN function pre- and postoperatively.

Before the surgery, 8 (57.1%) patients had caudal CN group function deficit. After the surgery, it remained at the same level in 7 patients. Only one of these patients had postoperative deterioration of the existing caudal CN group dysfunction.

6 (42.9%) patients had no caudal CN group dysfunction before the surgery. 5 patients developed a new neurological

**Table 2.** Clinical characteristics of operated patients

No.	Gender	Tumor type	Approach	Resection volume	Preoperative CN deficit*			Postoperative CN deficit*		
					VII	VIII	Caudal group	VII	VIII	Caudal group
1	F	A	Retrosigmoid	Subtotal	-	2	Dysphonia, dysarthria Dysphagia	-	2	Dysphonia, dysarthria Dysphagia
2	F	D	Retrosigmoid, extended, with foramen magnum semicircle and C1 resection	Partial	2	5	Dysphonia	2	5	Dysphagia Dysphonia
3	F	D	Retrosigmoid	Subtotal	-	5	Dysphagia	2	3	Dysphagia
4	F	A	Retrosigmoid	Subtotal	-	-	Dysphagia Dysarthria	-	-	Dysphagia Dysarthria
5	F	D	Retrosigmoid, extended	Partial	-	2	-	-	2	Dysphagia Dysphonia
6	F	A	Retrosigmoid, extended, with foramen magnum semicircle and C1 resection	Subtotal	-	3	-	-	4	Dysphagia Dysphonia
7	M	B	Retrosigmoid	Total	2	4	-	3	5	Dysphonia, dysarthria Dysphagia
8	M	B	Retrosigmoid	Partial	-	5	Dysphonia Dysarthria	-	3	Dysphonia Dysarthria
9	M	A	Retrosigmoid	Total	-	2	-	-	2	Dysphagia Dysphonia
10	F	D	Retrosigmoid	Subtotal	-	2	-	2	2	Dysphagia Dysphonia
11	M	D	Retrosigmoid	Partial	-	2	-	-	2	Nerve XII palsy
12	M	D	Retrosigmoid	Subtotal	-	2	Dysphonia	-	2	Dysphonia
13	M	A	Retrosigmoid	Subtotal	2	2	Dysphagia Dysphonia	5	2	Dysphagia Dysphonia
14	F	A	Retrosigmoid, extended, with foramen magnum semicircle and C1 nipping	Total	-	5	Dysphagia Dysphonia	5	5	Dysphagia Dysphonia

\*Note: facial nerve function is assessed as per the HBS and hearing functions as per GRS

deficit in the caudal CN group postoperatively. And only in one case there was no neurological deficit, either pre- or postoperatively. The presented material proved no statistical dependence of a new deficit on the tumor type or completeness of its removal.

3 (21.4%) patients had preoperative FN deficit (HBS Grade II) and mild dysfunction. 5 (35.7%) patients had postoperative facial nerve deficit: HBS II, 2; III, 1; V, 2. In two cases, the already existing mild FN dysfunction after surgery worsened to moderate and severe dysfunction, respectively. A new facial nerve deficit developed in type A and D tumors (2 cases each) and type B tumors (1 case).

Preoperative sensorineural type hearing impairment on the affected side was diagnosed in 13 (92.6%) patients. Preoperatively, 4 (28.6%) patients were diagnosed with anacusia (grade V) on the affected side (as per GRS), one patient grade IV hearing loss and one patient grade III hearing loss. In 2 (14.3%) cases, hearing deteriorated from grade III to grade IV after surgery; in 4 patients from grade IV to grade V. In 2 (14.3%) cases, hearing improved from grade V to grade III after surgery. Therefore, before surgery, 6 patients had non-serviceable hearing, which remained at the same level after surgery. None of the patients with grade I or II hearing before surgery had any hearing impairment postoperatively.

No patient had pre- or postoperative nerve XI dysfunction. One (7.1%) patient had CN XII deficit after surgery.

Bradycardia was a more frequent intraoperative complication, which was diagnosed in 3 (21.4%) cases. In one of these patients, the surgical intervention was ended after partial tumor removal due to difficult-to-control bradycardia. In only one case, tumor removal was accompanied by intense bleeding. Postoperatively, four patients underwent temporary nasogastric tube insertion to prevent aspiration pneumonia. Two of these 4 patients also underwent tracheostomy due to severe bulbar palsy (removed tumors in these patients were of type A).

### Discussion

Schwannomas growing near jugular foramen originate from CNs IX–XI. In most cases, GNS is diagnosed. [4]. In our series, the diagnosis of glossopharyngeal nerve schwannoma was confirmed radiologically, intraoperatively, and histologically. Clinical symptoms of such tumors depend more on tumor spread than on the nerve from where the tumor originates. [5].

According to the literature, hearing loss is a frequent manifesting symptom, which is more typical of type A tumors. This fact motivates a detailed differential diagnosis in case of vestibular schwannomas. [6]. In our study, 13 (92.6%) patients had preoperative hearing loss of varying severity on the affected side. Differential diagnosis should be also carried out in JF meningiomas and jugular glomus tumors. Radiologically, jugular foramen schwannoma is characterized by jugular foramen expansion and sclerosing of its edges. At the same time, in case of meningiomas, jugular process and tubercle hyperostosis is diagnosed. In jugular glomus tumors, erosion and bone destruction are found. [7].

The key goal of surgical jugular foramen schwannomas treatment is to ensure total tumor removal while preserving the CN function. Some researchers prefer one-stage surgery as reoperation can cause severe CN deficit due to the scarring from previous surgeries. [5,8,9]. In addition, multi-center studies have shown that stereotactic radiosurgery can ensure acceptable tumor control and improve neurologic function in most patients with primary or residual schwannomas. [10].

Based on the literature data, the retrosigmoid approach is suitable for type A tumors removal. The disadvantage of such approach is the impossibility of complete removal of the intraforaminal and extracranial parts of the tumor. For type B, C, and D tumors, other lateral approaches to the skull base are required (**Table 3**) [11].

In our series, in 3 (21.4%) cases, an extended retrosigmoid approach with foramen magnum semicircle and C1 vertebra was applied. Extended approaches were used in cases of type A tumors (2 patients) and type D tumor (1 patient). The reasons for selecting such approaches were as follows: compression of pons, medulla oblongata, and the fourth ventricle, pronounced caudal tumor growth up to foramen magnum, and an increased risk of development or decompensation of already existing occlusive hydrocephalus. In case of preoperative occlusive hydrocephalus, craniovertebral junction decompression was supplemented with ventriculocisternal shunting as per Torkildsen.

One type D tumor patient underwent a retrosigmoid approach with endoscopic assistance, which helped remove the intraforaminal part of the tumor. Thus, it was possible to ensure a subtotal tumor resection, given its small extracranial spread.

**Table 3.** Surgical approach dependence on the type of jugular foramen schwannoma [3].

Group	Approach
A	Retrosigmoid
B1	EA-RS infralabyrinthine (suprajugular) approach
B2	EA-RS infralabyrinthine (suprajugular) approach
B3	EA-transcervical approach
C	Transcervical approach
D	Combined transcervical and EA-RS infralabyrinthine (suprajugular) approach

\*Note: EA-RS = retrosigmoid approach with endoscopic assistance

The infratemporal fossa approach described by Fisher ensures a direct access to the jugular foramen. [12]. However, the disadvantage of this method is the high risk of facial nerve damage and hearing loss. Samii et al. suggest using certain approaches depending on tumor characteristics. [3].

In our series, retrosigmoid approach was used for all patients. In only one case, the extracranial part of type D tumor was removed using transcervical approach at the first treatment stage.

The most common complication after jugular foramen schwannoma removal is a caudal group nerves dysfunction, manifested by phonation disorder, dysphagia, and inability to protect the airway, which causes frequent aspiration. Impaired swallowing mechanism can be compensated in patients with preoperative slowly progressive caudal nerve function disorder. At the same time, development of acute caudal nerves group deficit is more dangerous. This condition may cause life-threatening aspiration. Therefore, a nasogastric tube can be inserted during the patient's extubation and remain until the patient swallows normally. If swallowing remains impaired for 2 weeks, a tracheostomy is temporarily performed. In case of long recovery or frequent aspirations, a gastrostomy tube may be required. [3,13].

Postoperatively, 2 patients (14.3%) underwent tracheostomy and a nasogastric tube was inserted due to pronounced bulbar palsy — both tumors were of type A. Another two patients underwent nasogastric tube insertion for 7–10 days without tracheostomy. In our series, patients with preoperative bulbar palsy, had clinically less pronounced caudal group dysfunction. According to the literature, this is explained by the development of compensatory mechanisms as the tumor grows; on the contrary, acute damage to the caudal group of nerves causes the development of pronounced bulbar palsy. Overall, 6 (42.9%) patients developed a new neurological deficit in the caudal CN group.

Postoperative facial and auditory nerve deficits are not a common complication when such tumors are removed using a retrosigmoid approach [14]. In our series, only 2 patients had a pronounced facial nerve deficit (House-Brackmann score 5). In both cases, the tumor was of type A and had a maximum diameter of more than 4 cm. One patient underwent repeated tumor removal. 2 patients had hearing loss as per Gardner-Robertson Scale, but it was not a significant indicator as these patients had non-serviceable hearing preoperatively. On the contrary, in one patient the hearing improved but, unfortunately, did not reach a serviceable level.

Schwannomas rarely affect the surrounding structures, which can be usually released after sufficient internal decompression. To minimize damage to the cranial nerves, resection should be performed while preserving residual tumor tissue or arachnoid layer to the maximum extent. Intraoperative neurophysiological monitoring plays an important role in maintaining the CN function. The use of endoscopic techniques will optimize the approach. [14].

### Conclusions

Tumor location and spread before the surgery is an important stage in the preoperative assessment and surgery planning, as it allows selecting the most suitable

approach. Applying a retrosigmoid approach only makes it possible to achieve total tumor removal in case of type A tumors. To remove other tumor types, it is necessary to select approaches that enable access to the jugular foramen and infratemporal fossa.

The use of a retrosigmoid approach with endoscopic assistance allows for desired completeness of resection of type A, B1, and B2 tumors. To remove type D tumors, it is possible to use this approach in combination with a transcervical approach.

The most common postoperative complication is a developed or increased deficit of the caudal CN group, which can lead to persistent impairments in the patients' quality of life. Preservation of the CN function in most cases is a feasible task and should be ensured as a standard for this pathology.

Intraoperative neurophysiological monitoring during glossopharyngeal nerve schwannomas removal is an important tool in preserving the anatomical integrity and functional preservation of the cerebellopontine angle CNs.

Incomplete tumor removal in case of its close contact with important neurovascular structures is one of the ways to prevent severe neurological deficits. Subsequent use of adjuvant radiation therapy has shown good results in controlling continued tumor growth.

### Disclosure

#### *Conflict of interest*

The authors declare no conflict of interest.

#### *Ethical approval*

All procedures performed in studies involving human participants were in accordance with the ethical standards of the institutional and national research committee and with the 1964 Helsinki declaration and its later amendments or comparable ethical standards.

#### *Informed consent*

The written informed consent was obtained from each patient or appropriate family member before the surgery.

#### *Funding*

The research had no sponsor support.

### References

1. Sanna, M., Bacciu, A., Falcioni, M., & Taibah, A. (2006). Surgical Management of Jugular Foramen Schwannomas With Hearing and Facial Nerve Function Preservation: A Series of 23 Cases and Review of the Literature. *The Laryngoscope*, 116(12), 2191–2204. doi:10.1097/01.mlg.0000246193.843
2. Ramina, R., Maniglia, J. J., Fernandes, Y. B., Paschoal, J. R., Pfeilsticker, L. N., & Neto, M. C. (2005). Tumors of the Jugular Foramen: Diagnosis and Management. *Operative Neurosurgery*, 57, 59–68. doi:10.1227/01.neu.0000163483.447
3. Samii M, Alimohamadi M, Gerganov V. Surgical Treatment of Jugular Foramen Schwannoma: Surgical Treatment Based on a New Classification. *Neurosurgery*. 2015 Sep;77(3):424–32; discussion 432. doi: 10.1227/NEU.0000000000000831
4. Wilkins RH, Rengachary SS, editors. 2nd ed., *Neurosurgery*, vol. 2, 2nd ed. New York: McGraw-Hill; 1996. p. 1553–7.
5. Kadri PA, Al-Mefty O. Surgical treatment of dumbbell-shaped jugular foramen schwannomas. *Neurosurg Focus*. 2004 Aug 15;17(2):E9. doi: 10.3171/foc.2004.17.2.9
6. Nowak A, Dziedzic T, Czernicki T, Kunert P, Marchel A. Surgical treatment of jugular foramen schwannomas. *Neurol Neurochir Pol*. 2014;48(3):188–95. doi: 10.1016/j.pjnns.2014.05.004
7. Kankane VK, Warade AC, Misra BK. Nonvestibular

- Schwannoma Tumors in the Cerebellopontine Angle: A Single-Surgeon Experience. *Asian J Neurosurg.* 2019 Jan-Mar;14(1):154-161. doi: 10.4103/ajns.AJNS\_335\_17
8. Sedney CL, Nonaka Y, Bulsara KR, Fukushima T. Microsurgical management of jugular foramen schwannomas. *Neurosurgery.* 2013 Jan;72(1):42-6; discussion 46. doi: 10.1227/NEU.0b013e3182770e74
  9. Samii M, Migliori MM, Tatagiba M, Babu R. Surgical treatment of trigeminal schwannomas. *J Neurosurg.* 1995 May;82(5):711-8. doi: 10.3171/jns.1995.82.5.0711
  10. Kano H, Meola A, Yang HC, Guo WY, Martínez-Alvarez R, Martínez-Moreno N, Urgosik D, Liscak R, Cohen-Inbar O, Sheehan J, Lee JYK, Abbassy M, Barnett GH, Mathieu D, Kondziolka D, Lunsford LD. Stereotactic radiosurgery for jugular foramen schwannomas: an international multicenter study. *J Neurosurg.* 2018 Oct;129(4):928-936. doi: 10.3171/2017.5.JNS162894
  11. Ryu SM, Lee JI, Park K, Choi JW, Kong DS, Nam DH, Jeong HS, Cho YS, Seol HJ. Optimal treatment of jugular foramen schwannomas: long-term outcome of a multidisciplinary approach for a series of 29 cases in a single institute. *Acta Neurochir (Wien).* 2017 Aug;159(8):1517-1527. doi: 10.1007/s00701-017-3230-0
  12. Wilson, M.A., Hillman, T.A., Wiggins, R.H. and Shelton, C. (2005), Jugular Foramen Schwannomas: Diagnosis, Management, and Outcomes. *The Laryngoscope*, 115: 1486-1492. doi.org/10.1097/01.mlg.0000172196.76865.a1
  13. Zeng XJ, Li D, Hao SY, Wang L, Tang J, Xiao XR, Meng GL, Jia GJ, Zhang LW, Wu Z, Zhang JT. Long-Term Functional and Recurrence Outcomes of Surgically Treated Jugular Foramen Schwannomas: A 20-Year Experience. *World Neurosurg.* 2016 Feb;86:134-46. doi: 10.1016/j.wneu.2015.09.104
  14. Wang X, Long W, Liu D, Yuan J, Xiao Q, Liu Q. Optimal surgical approaches and treatment outcomes in patients with jugular foramen schwannomas: a single institution series of 31 cases and a literature review. *Neurosurg Rev.* 2020 Oct;43(5):1339-1350. doi: 10.1007/s10143-019-01165-6