

Ukr Neurosurg J. 2021;27(2):41-48  
doi: 10.25305/unj.227762

## Treatment outcomes and objectification methods of the thoracoscopic sympathectomy in patients with focal hyperhidrosis and blushing syndrome

Oleksiy A. Eroshkin<sup>1,2</sup>, Vitaliy V. Sokolov<sup>3</sup>, Anastasiia V. Omelchenko<sup>2,4</sup>, Iryna R. Luzhenetska<sup>5</sup>, Dmytro M. Romanukha<sup>1</sup>

<sup>1</sup> Department of Neurosurgery, Central Hospital of the Ministry of Internal Affairs of Ukraine (Central Police Hospital), Kyiv, Ukraine

<sup>2</sup> Medical Center "MedClinic", Kyiv, Ukraine

<sup>3</sup> Department of Thoracic Surgery and Pulmonology, Shupyk National Healthcare University of Ukraine, Kyiv, Ukraine

<sup>4</sup> Department of General Surgery No 2, Bogomolets National Medical University, Kyiv, Ukraine

<sup>5</sup> Clinic "EuroDerm Clinic", Kyiv, Ukraine

Received: 26 March 2021

Accepted: 27 April 2021

### Address for correspondence:

Dmytro M. Romanukha, Department of Neurosurgery, Central Hospital of Ministry of Internal Affairs of Ukraine (Central Police Hospital), 1 Berdychivska str., Kyiv, 04116, Ukraine, e-mail: neuromanukha@gmail.com

Uniportal video-assisted thoracoscopic sympathectomy (VATS) is an effective minimally invasive surgical method of choice for the treatment of primary focal hyperhidrosis and blushing syndrome due to uncontrolled operation of the sympathetic nervous system.

**The aim** of this study was to provide an objective assessment of the improvement in the quality of life of patients with primary focal hyperhidrosis and blushing syndrome after bilateral monoport video-assisted thoracoscopic sympathectomy.

**Materials and methods.** The results of surgical treatment were performed for 62 patients aged 17 to 42 years, 26 men and 36 women with a diagnosis of primary focal hyperhidrosis of the extremities and blushing syndrome. All patients underwent bilateral uniport video-assisted thoracoscopic sympathectomy. Patients are divided into 3 groups depending on the level of coagulation of the sympathetic trunk: the first group of the study (n=9) includes patients after bilateral uniport sympathectomy at the level of R3 (isolated palmar hyperhidrosis), the second (n=31) - at the level of R3-R4 (palmar and axillary hyperhidrosis), the third group (n=22) - at the level of R2 (blushing syndrome).

**Results.** In this study, coagulation and separation of the sympathetic trunk through a single port using a silicone port was performed. An excellent clinical result was achieved due to the minimally invasive operation - all 62 patients (100%) were satisfied with the achievement of a rapid stable effect. According to the results of the Dermatology Life Quality Index DLQI (1 month after surgery), the best quality of life measures were observed in patients who underwent separation of the sympathetic trunk at the R3 level - improvement from  $20.3 \pm 5.9$  points to  $0.8 \pm 0.8$  points. After the operation at the R3-R4 level scores the quality of life decreased from  $22.77 \pm 5.4$  points to  $2.3 \pm 1.3$  points, and at the level of R2 - from 16.5 points ( $Q_I$  14 points -  $Q_{III}$  20 points) to 2 points ( $Q_I$  1 point -  $Q_{III}$  3 points) ( $p < 0.001$ ).

There was a difference in quality of life measures in our three groups of patients according to the severity of the disease before surgery. The lowest quality of life was determined in patients with the 4th degree of severity (33 people) and was 26.0 points ( $Q_I$  23.0 points -  $Q_{III}$  27.3 points) compared with patients with 2d and 3d degrees of severity, 10.0 points ( $Q_I$  7.7 points -  $Q_{III}$  10.0 points) and 17.0 points ( $Q_I$  14.0 points -  $Q_{III}$  19.5 points) respectively ( $p < 0.001$ ). After a single-port VATS in three groups there was an increase in quality of life measure, regardless of the severity of the disease before surgery.

**Conclusions.** The most highly specific tests that allow to determine an objective assessment of the severity of the disease and a real assessment of the effectiveness of surgical treatment for hyperhidrosis was TEWL-metry, for blushing syndrome - capillaroscopy.

VATS is an effective method of treating patients with hyperhidrosis and blushing syndrome, which significantly improves the quality of life according to the results of the Dermatological Index of Life Quality DLQI ( $p < 0.001$ ) questionnaire.

**Key words:** hyperhidrosis; sympathectomy; blushing syndrome; TEWL-metry; capillaroscopy; quality of life

### Introduction

Single-port video-assisted thoracoscopic sympathectomy (VATS) is an effective minimally invasive surgical method of choice for the treatment of primary focal hyperhidrosis, which is caused by pathological hyperactivity of the sympathetic part of the autonomic nervous system [1-3]. Today, this method is also widely used for the treatment of blushing syndrome, a

characteristic symptom of which is uncontrolled frequent and intense attacks of redness of the face and neck [4].

Symptoms of decompensated hyperhidrosis of the palms, armpits and feet significantly affect the quality of life, in particular the physiological, mental and social situation of the patient [5,6]. Conservative treatment only temporarily reduces symptoms, while surgical treatment is the most effective and is based on inhibiting



the transmission of impulses from the sympathetic ganglia to the exocrine sweat glands [7].

Thoracoscopic sympathectomy was first proposed in 1942 by J. Hughes. It remained almost unknown until the widespread introduction of video endoscopic techniques in the 1980s [8]. However, when choosing surgical treatment, many questions remain relevant, including the determination of the degree, the number of degrees and the method of interruption of the sympathetic chain [5]. Traditional methods of diagnostic tests to determine the severity of focal hyperhidrosis and blushing syndrome have a number of disadvantages, which require the search for new diagnostic methods to objectify the severity of symptoms in these diseases and the results of surgical treatment.

**Objective:** To conduct an objective assessment for the improvement of the quality of life of patients with primary focal hyperhidrosis and blushing syndrome after bilateral single-port video-assisted thoracoscopic sympathectomy.

### Materials and methods

#### Study participants

The analysis of results of surgical treatment of 62 patients aged 17 to 42 years, including 26 (41.9%) men and 36 (58.0%) women who were inpatient treatment at the Medical Center "MedClinic" in 2015-2021.

All patients gave written informed consent to participate in the study and use its results for the scientific purpose.

The study was approved by Ethics and Bioethics Committee of "MedClinic" Medical Center (Meeting Minutes No. 1 of March 30, 2016).

The study is not associated with an increased risk for study subjects and was carried out in accordance with bioethical norms and scientific standards for conducting clinical trials with the participation of patients.

#### Inclusion / exclusion criteria

Criteria for recruiting the patients in the study: males and females aged 16 to 60 years; diagnosed with "primary focal hyperhidrosis of the extremities" and / or "blushing syndrome"; ineffectiveness of conservative

treatment; performed surgical intervention - bilateral single-port VATS.

Exclusion criteria from the study: persons under the age of 16; patients with secondary hyperhidrosis; patients with mental disorders under the dispensary supervision of a psychiatrist; patients who underwent thoracoscopic sympathectomy for indications other than primary hyperhidrosis and blushing syndrome; inability to continue participating in the study during the follow-up period.

#### Characteristics of the group

Patients were divided into three groups depending on the level of coagulation of the sympathetic trunk: the first group (n=9) - bilateral single-port sympathectomy at the level of R3 (isolated palmar hyperhidrosis), the second group (n=31) - at the level of R3-R4 (hyperhidrosis of the palms and armpits), the third group (n=22) - at the level of R2 (blushing syndrome).

#### Study design

All patients underwent single-port VATS according to the following method [9]:

1. General anesthesia was given with intubation of the lungs with a double lumen tube.

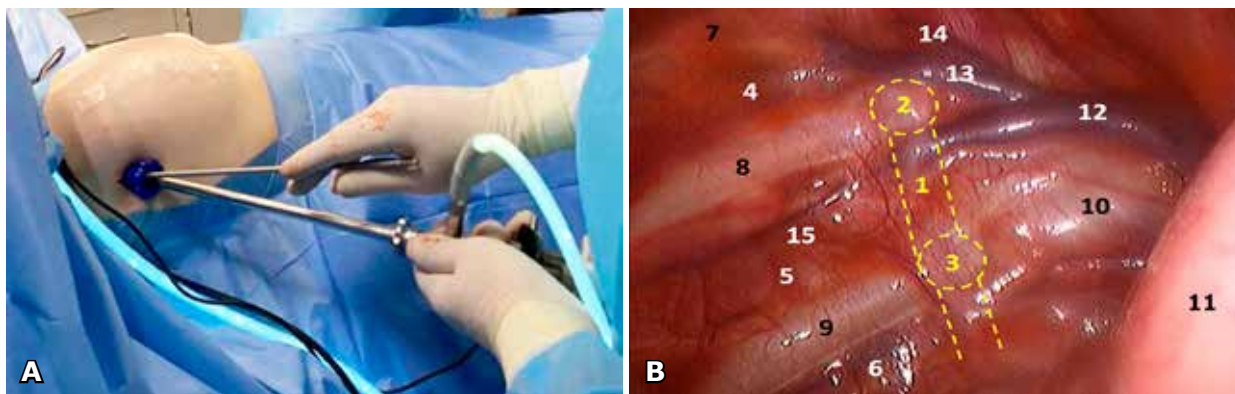
2. The position of the patient on the operating table is on the back with the upper extremities at 90°.

3. A 15 mm skin incision was performed in the III-IV intercostal space along the anterior-axillary line. A 10 mm trocar was inserted into the III-IV intercostal space and tissue dissection was performed from the skin to the parietal pleura with its perforation (pneumothorax). The lumen of the endotracheal tube, which ventilates the lung was opened on the side of the operation. This caused the collapse of the lung on this side. A 20-millimeter silicone trocar was inserted, through which a 30-degree thoracoscope was inserted into the pleural cavity (**Fig. 1A**).

4. After revision of the pleural cavity, a curved monopolar hook was inserted, which was used to coagulate the sympathetic trunk.

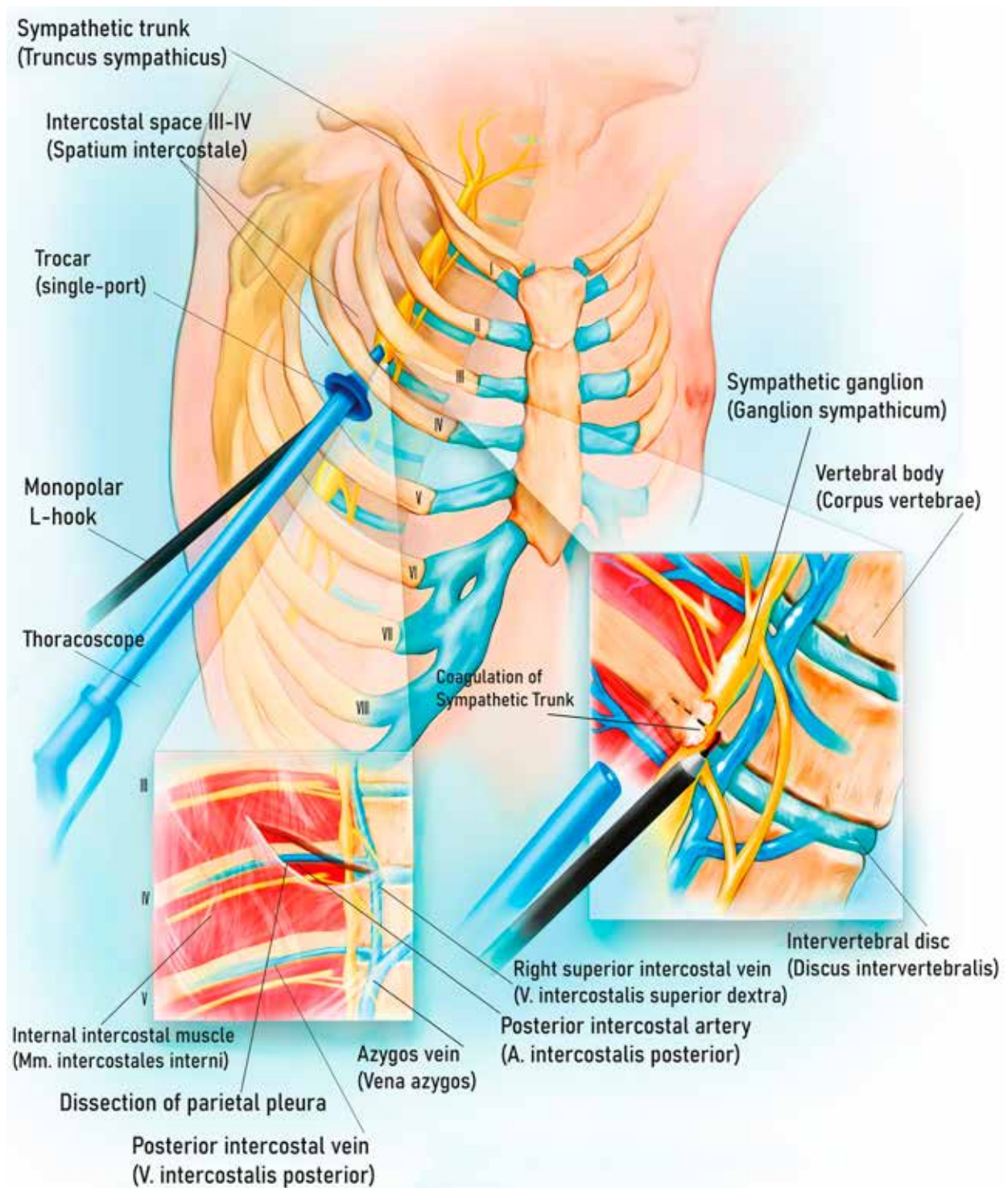
5. The required level of the sympathetic trunk was determined by anatomic landmarks. (**Fig. 1B**).

6. The mediastinal pleura of the corresponding rib in the area of 4 cm and the sympathetic trunk were coagulated at this level between the two ribs (**Fig. 2**).



**Fig. 1.** Intraoperative photo of monoportal thoracoscopic sympathectomy: A - position of the trocar for single-port VATS; B - visualization of the sympathetic trunk in a single-port VATS: 1 - sympathetic trunk; 2 - II sympathetic ganglion; 3 - III sympathetic ganglion; 4 - the second intercostal space; 5 - the third intercostal space; 6 - the fourth intercostal space; 7 - II rib; 8 - III rib; 9 - IV rib; 10 - vertebra; 11 - lung; 12 - azygos vein; 13 - right superior intercostal vein; 14 - posterior intercostal vein; 15 - posterior intercostal artery

This article contains some figures that are displayed in color online but in black and white in the print edition



**Fig. 2.** Single-port video-assisted thoracoscopic sympathectomy

7. After coagulation of the sympathetic trunk and its collateral innervation (Kuntz nerves), a drainage tube 18 Fr with water valve through the trocar into the thoracic cavity was inserted to control the lung expansion with increasing airway pressure by artificial ventilation. After the complete expansion of the lung, the drainage was removed and layered closure of the wound was made.

8. A cosmetic suture was applied to the skin and an aseptic dressing.

Dermatology Life Quality Index (DLQI) questionnaire [10] and Hyperhidrosis Disease Severity Scale (HDSS) were used to assess the quality of life before and after surgery [11]. A scale from 0 to 30 points was used to assess DLQI: 0–1 points - symptoms did not affect the patient's quality of life, 2–5 points - had little effect, 6–10 points - had a moderate effect, 11–20 points - had a significant effect, 21–30 points - had an extremely large effect. To determine the degree of hyperhidrosis,

traditional examination methods were used – Minor test and the gravimetric analysis. The latter was performed with high-precision weighing of filter paper up to 0.01 g. Capillaroscopy was performed in case of blushing syndrome.

To determine the objective assessment of the severity of hyperhidrosis, measurements of transepidermal fluid loss (TEWL-metry) were carried out before and after surgery (in 1 month) using a Tewameter TM 300 apparatus with an open chamber. The unit of measurement is g / h / m<sup>2</sup> [12,13]. According to the degree of transepidermal fluid loss the skin condition was determined: 0–10 - excellent condition, 10–15 - satisfactory condition, 15–25 - normal condition, 25–30 - stressful condition, > 30 - critical condition. Conditions for the testing procedure: in the morning, during the day the exposure to the study site of antiperspirants, moisturizers, alcohol-containing solutions of antiseptics was excluded. Before the study, the patient was indoors for 30 minutes at an air humidity of 20-40% and a temperature of 20–22° C.

#### Statistical analysis

When processing the statistical data, the arithmetic mean and standard deviation score or median and the interquartile interval (QI – QIII) were determined. To identify differences after surgical treatment Student's test was used for related samples in the case of a normal data distribution law, and Wilcoxon rank sum test was used for linked samples with distribution of data other than normal. To determine the difference between the groups according to the severity of the disease, multiple comparisons were made and Kruskal-Wallis H test was used. Dunnett comparisons post hoc test were made. Statistical data processing was performed using the EZR package EZR v. 1.54 (R statistical software version 4.03, R Foundation for Statistical Computing, Vienna, Austria) [14]. When analyzing the research results the critical significance level was taken as 0.05.

#### Results

Patients underwent single-port bilateral VATS: 9 (14.5%) patients with palmar hyperhidrosis, 31 (50%) with palmar, axillary and plantar hyperhidrosis, and 22 (35.5%) with blushing syndrome. The median age was 25 years (17 to 42 years).

Among patients with hyperhidrosis, the 2nd degree of severity according to the HDSS scale was found in 2 (5.0%) persons, the 3rd degree in 11 (27.5%), the 4th degree in 27 (67.5%) . The length of hospital stay averaged (1.00 ± 0.41) days.

After surgery, all patients were satisfied with the result. There were no postoperative complications in all study groups, including Bernard-Horner syndrome, fatalities, and conversion of VATS to open surgery. No recurrences of the disease were recorded throughout the follow-up period (one year).

The results of surgery at various levels of the sympathetic trunk and its impact on quality of life were assessed using the DLQI questionnaire. One month after surgery, the best quality of life measures were recorded in patients who underwent transection of the sympathetic trunk at the level of R3 (improvement from (20.3 ± 5.9) to (0.8 ± 0.8) points), whereas after surgery at the level of R3-R4 the quality of life improved from (22.77 ± 5.4) to (2.3 ± 1.3) points, and after the surgery at the level of R2 - from 16.5 [14; 20] to 2.0 [1; 3] points (p <0.001).

Compensatory hyperhidrosis of varying severity in patients who underwent VATS regressed in all cases

during the first year. Only 10 (16%) people reported symptoms of compensatory hyperhidrosis in the area of trunk, abdomen, back, inner thigh during sports physical training or when the air temperature rises above 30° C. In everyday life, the phenomena of compensatory hyperhidrosis were not observed. This did not affect the quality of life and satisfaction with the outcome of surgical treatment.

Comparison in the study groups revealed a difference in quality of life measures depending on the severity of the disease before surgery. The lowest quality of life measure was observed in patients with the 4th degree of severity - 26.0 [23.0; 27.3] points compared with patients with the 2nd and 3rd degree of severity - 10.0 [7.7; 10.0] and 17.0 [14.0; 19.5] points, respectively (p <0.001). After performing a single-port VATS in three groups, an increase in quality of life measure was registered regardless of the severity of the disease before surgery: in the 2nd degree of severity - 2.0 [1.0; 2,3] points, in the 3rd degree - 2,0 [0,5; 2.0] points, in the 4th degree - 2.0 [1.0; 3.0] points (p <0.001).

#### Clinical case 1

Patient M., born in 1985, complained of frequent and intense attacks of redness of the skin of the face and neck, accompanied by a sensation of "hot flashes". Symptoms appeared during adolescence.

On physical examination: with a slight stress factor, hyperemia of the face and neck, and areas of chest occurs (**Fig. 3, 5**).

Differential diagnosis was made with hyperthyroidism, pheochromocytoma.

According to the results of capillaroscopy: signs of microcirculatory disorders, local vascular tortuosity of the afferent arteriolar vessels, congestion in the postcapillary-venular vessels, pronounced perivascular edema (see **Fig. 3, 5**).

On September 28, 2020, a thoracoscopic sympathectomy was performed. Bilateral VATS at the level of R2. The postoperative period was uneventful.

Result: long -lasting effect from the moment of surgery - no redness attacks (**Fig. 4, 6**). After the operation according to DLQI - 2 points.

#### Clinical case 2

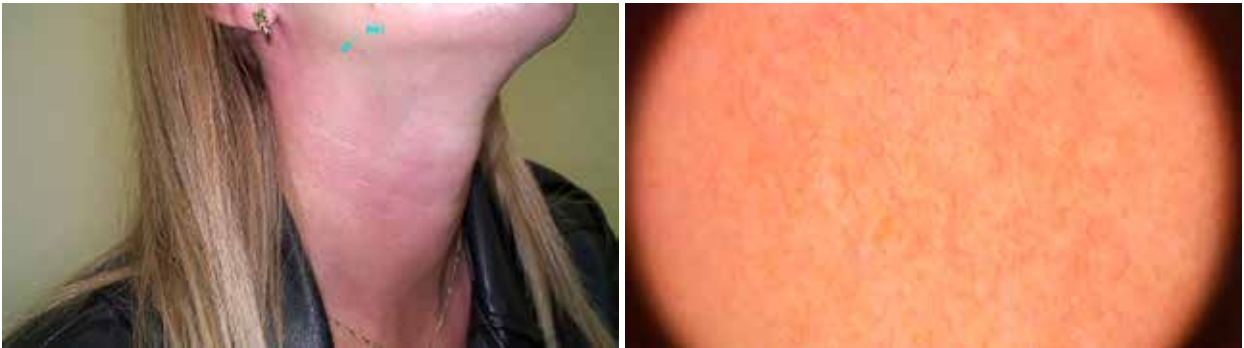Patient O., born in 2001, complained of increased sweating of the palms and armpits. The diagnosis of primary palmar and axillary hyperhidrosis of the 3rd degree was made.

On physical examination: palms and armpits are cool and moist to the touch (**Fig. 7A, 7B**).

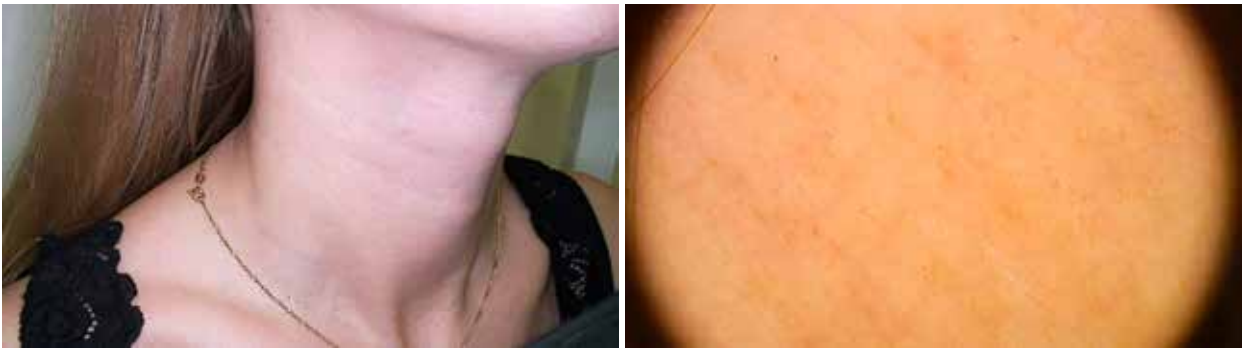Differential diagnosis was made with hyperthyroidism, pheochromocytoma.

TEWL test results, g / h / m<sup>2</sup>:

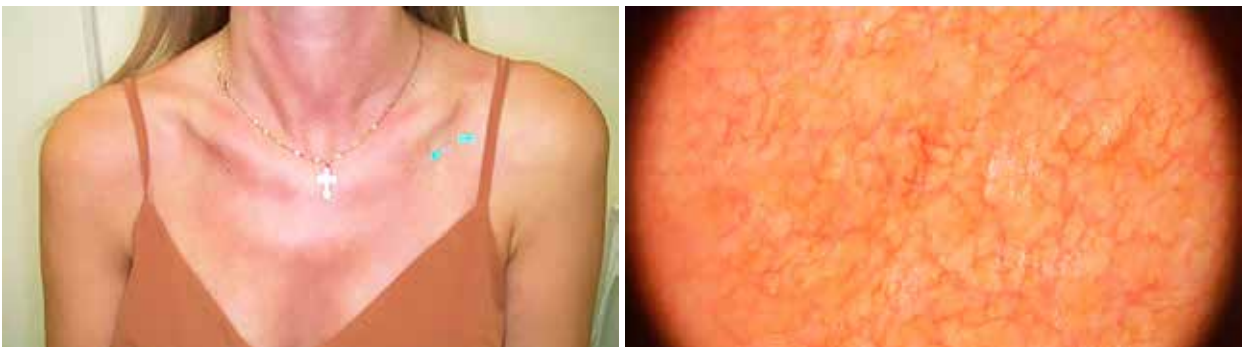Area	TEWL before surgery	TEWL after surgery
Right palm	49.1	20.4
Left palm	46.5	23.7
Right axillary region	48.5	21.0
Left axillary region	47.3	22.5
Right foot	26.8	22.2
Left foot	35.7	24.1



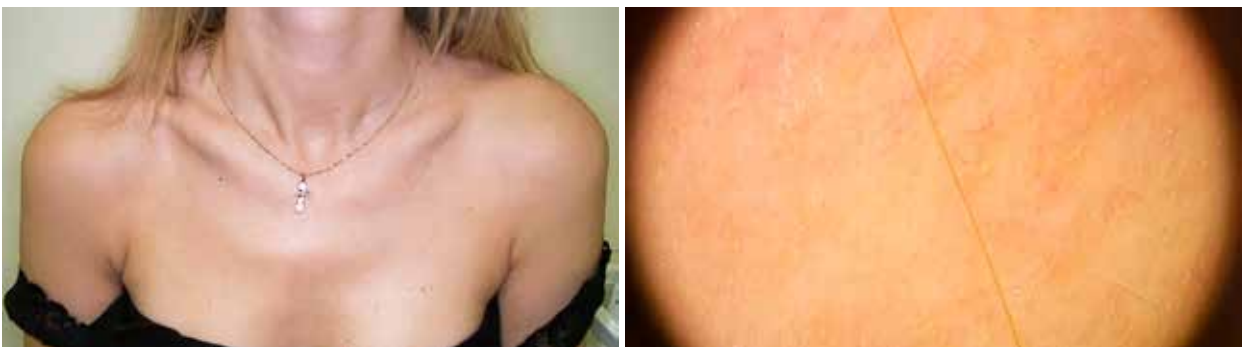**Fig. 3.** Capillaroscopy of patient K. before surgery (neck area). Multiple uniformly dilated capillaries against a prolonged erythematous background. Moderately tortuous capillaries, stagnant drops in curls, pronounced perivascular edema, venous insufficiency of the 1st degree



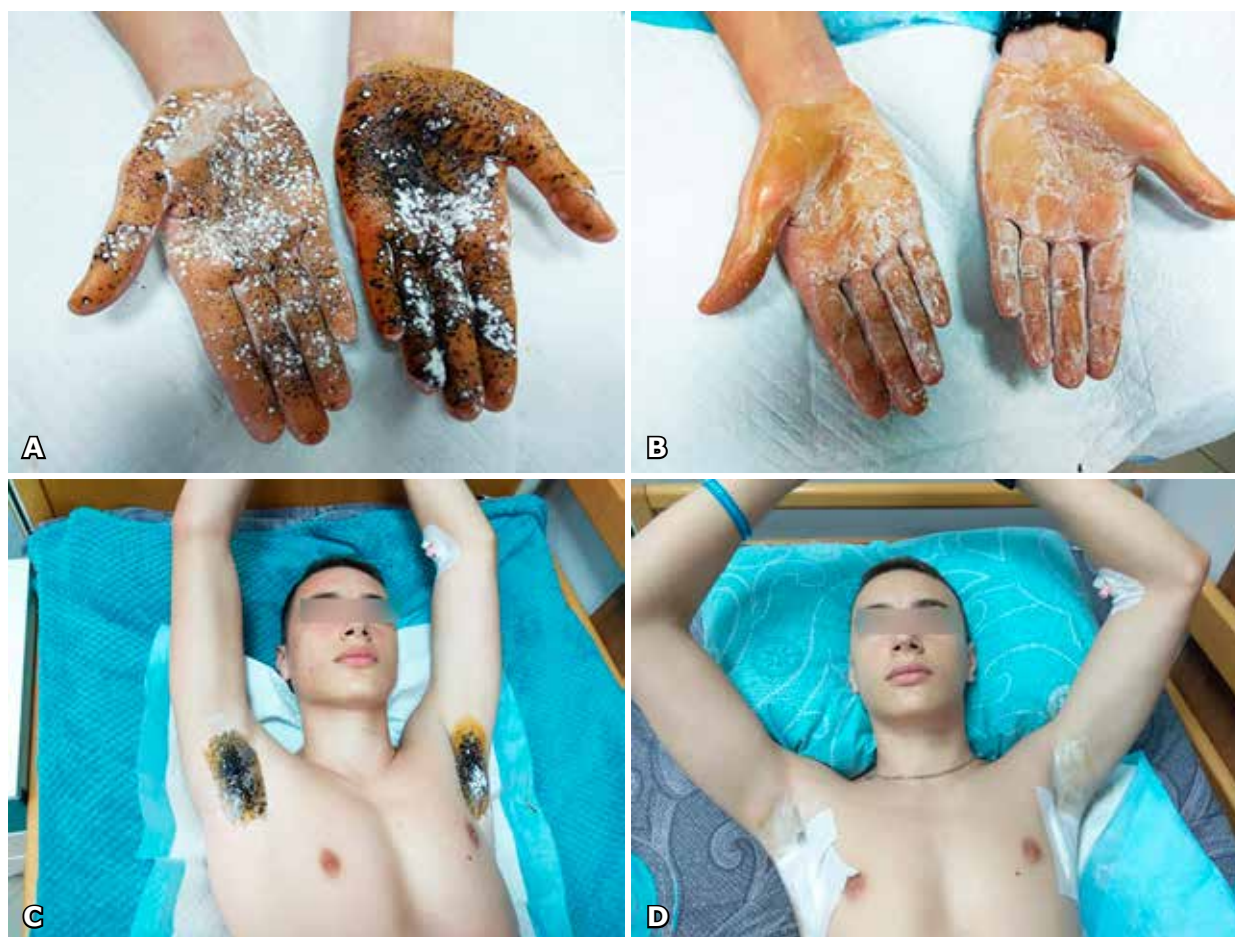**Fig. 4.** Capillaroscopy of patient K. after surgery (neck area). No prolonged erythema, normal diameter and shape of skin capillaries. The capillaroscopic picture is within the normal range for this anatomical area



**Fig. 5.** Capillaroscopy of the patient K. before surgery (chest area). Reticular vascular pattern on a prolonged erythematous background. Multiple telangiectasias. Secondary hyperpigmentation, represented by a pigmented pseudo grid



**Fig. 6.** Capillaroscopy of the patient K. after surgery (chest area). Clusters of reticular capillaries. No prolonged erythema. The capillaroscopic picture is within the normal range for this anatomical area. Uneven mild secondary skin hyperpigmentation



**Fig. 7.** Minor test in a patient with bilateral hyperhidrosis in the palms and axillary region: palms before (A) and after (B) surgery; armpits before (C) and after (D) surgery

Gravimetric analysis: on the right palm the result before surgery - 2.17 g, after surgery - 1.85 g, on the left palm the result before surgery - 2.11 g, the result after surgery - 1.78 g.

On July 14, 2020, a thoracoscopic sympathectomy was performed. Bilateral VATS at R3-R4 level.

Result: long-lasting effect from the moment of surgery - dry, warm palms and axillary regions (**Fig. 7B, 7D**). One month after surgery according to DLQI - 2 points.

### Clinical case 3

Patient K., born in 1992, complained of increased sweating of the palms.

On physical examination: wet palms, significant sweating from the palmar surface of both hands (**Fig. 8A**).

Differential diagnosis was made with hyperthyroidism, pheochromocytoma.

TEWL test results, g / h / m<sup>2</sup>:

Area	TEWL before surgery	TEWL after surgery
Right palm	44.9	22.0
Left palm	38.9	21.2
Right foot	20.2	19.5
Left foot	24.4	16.9

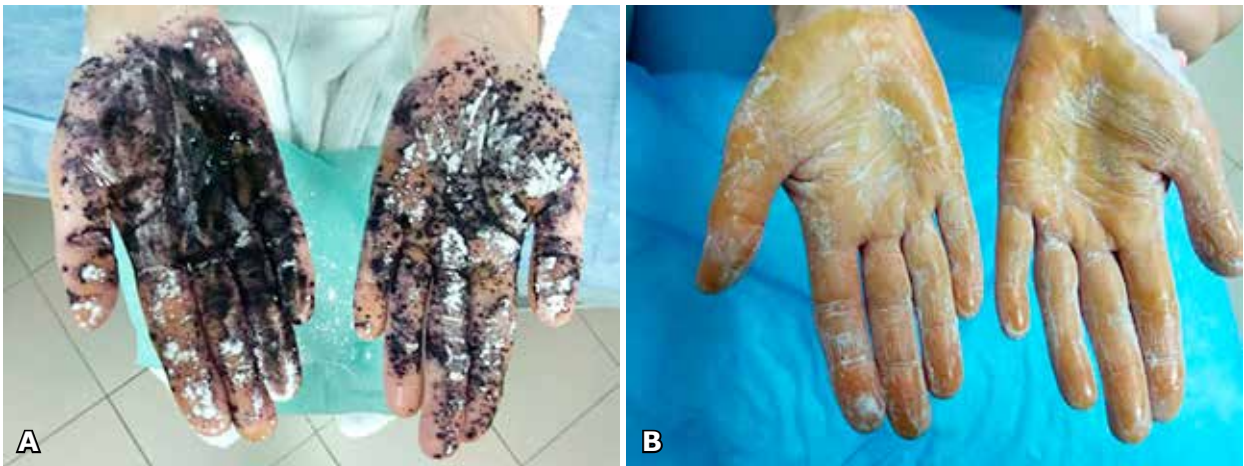Gravimetric analysis: on the right palm the result before surgery - 2.17 g, after surgery - 1.82 g, on the left palm the result before surgery - 2.11 g, after surgery - 1.79 g

On May 14, 2020, a thoracoscopic sympathectomy was performed. Bilateral VATS at R3 level. In the postoperative period, the patient did not notice the phenomenon of compensatory hyperhidrosis.

Result: long-lasting effect from the moment of surgery - dry, warm palms (**Fig. 8B**). One month after surgery according to DLQI - 0 points.

### Discussion

Currently, various approaches and methods of surgical treatment of upper limb hyperhidrosis and blushing syndrome are used, which involve the interruption of the upper thoracic sympathetic trunk, usually from the second to the fourth thoracic ganglion [15-17]. The most common are two- and three-portal VATS modifications. However, these approaches have a number of disadvantages compared to the single-portal approach due to the high trauma rate and the number of postoperative complications. In this study, coagulation and separation of the sympathetic trunk through a single port using a 20 mm diameter silicone port was performed by the authors. This operation was less traumatic for soft tissues, and an excellent clinical



**Fig. 8.** Minor test in a patient with bilateral hyperhidrosis on the palms before (A) and after (B) surgery

result was obtained - all patients were satisfied with the achievement of a quick effect.

Discussions continue on the optimal level of sympathectomy for a specific nosology with the most stable effect with the lowest risk of complications, side effects or disease recurrence. Thus, for the treatment of blushing syndrome or facial hyperhidrosis, it is recommended to perform a sympathectomy at the R3 or R2 and R3 levels, for the treatment of palmar hyperhidrosis - at the R3 or R4 levels, for the treatment of axillary hyperhidrosis - at the R4 and R5 levels or R5, for the treatment of combined palmar and axillary hyperhidrosis - at the R4 or R5 level [16]. Higher level of R2 sympathectomy is associated with the risk of Bernard-Horner syndrome due to possible damage to the cervicothoracic (stellate) ganglion or its branches. And too low levels (R5 and lower) threaten to damage the thoracic cardiac branches of the sympathetic trunk, which are involved in the formation of the cardiac plexus, and can cause cardiac arrhythmias [12,15,16].

A series of long-term studies by R. Jeganathan et al. found that sympathectomy provides a long-term positive effect without relapse, but compensatory hyperhidrosis is the most common side effect [18]. This is consistent with the data of most studies, according to which its frequency varies from 17 to 100% [16,19,20]. In our study, it was identified only 10 (16%) patients with compensatory hyperhidrosis of varying severity, which regressed in all cases within one year. This indicator is explained by the careful selection of patients for the surgery, which provided for highly specific preoperative diagnostic testing, much less traumatic techniques, as well as the correct determination of the level of sympathectomy. Some authors suggest that a larger volume of sympathectomy (up to R4 or R5 level) is associated with an increased risk of compensatory hyperhidrosis [15,20], which was also observed to a certain extent in our study. The highest rate was noted in the second group - 6 patients after VATS at two levels (R3-R4).

In the given clinical cases, TEWL-metry, traditional Minor test and gravimetric analysis were performed to determine the intensity of sweating.

Despite the simplicity of the Minor test and the high sensitivity of the test (up to 83%), this method

has certain disadvantages and low specificity (up to 57%) [21,22]. Gravimetric analysis is performed to quantify hyperhidrosis. The filter paper is weighed 60 s after contact with the area of increased sweating. The disadvantages of this method are the inability to determine the severity of hyperhidrosis (which is important when choosing a method of treatment), when the amount of sweat is not excessive.

Unlike the Minor test, which is used only to determine the limits of increased sweating, the main advantages of the TEWL test are the accuracy of transepidermal sweat loss and ease of implementation, which allows you to objectively assess the severity of hyperhidrosis and determine the indications for outpatient surgery. It was found that the condition of the skin with fluid loss 25–30 g / h / m<sup>2</sup> transepidermally corresponds to the intense, with fluid loss > 30 g / h / m<sup>2</sup> - critical. This may be a criterion for choosing the surgical treatment.

Patient K. with hyperhidrosis, who underwent a single-port VATS at the R3 level, in the postoperative period had a long-lasting effect from the moment of surgery, sweating from the palmar areas was reduced by half (from 44.9 to 22.0 g / h / m<sup>2</sup>) and axillary regions (from 48.5 to 21.0 g / h / m<sup>2</sup>), less noticeable changes were in the feet area (from 20.2 to 19.5 g / h / m<sup>2</sup>). On examination one month after surgery, the patient assessed the effect of sweating on quality of life as 0 points according to DLQI.

In patient M. with blushing syndrome capillaroscopy was performed to objectively assess changes in the skin of the face, neck and chest. In the postoperative period, regression of redness and the absence of prolonged erythema was observed, the capillaroscopic picture corresponded to norm for this anatomical region.

These results indicate that in order to objectively assess the severity of hyperhidrosis during the diagnostic examination of patients, it is necessary to perform TEWL-metry, and when examining persons with blushing syndrome - capillaroscopy.

The study carried out a comparative analysis of the results of a single-port bilateral VATS at different levels of the sympathetic trunk. The findings may be useful for neurosurgeons, thoracic surgeons, general surgeons, and family physicians.

## Conclusions

1. Single-port video-assisted thoracoscopic sympathectomy is an effective method of treating patients with hyperhidrosis and blushing syndrome, which significantly improves the quality of life according to the DLQI questionnaire ( $p < 0.001$ ).

2. Monoportal modification of VATS is optimal for minimally invasiveness, which allows patients to quickly recover after surgery and minimize the number of postoperative complications.

3. A high degree of patient selection, which provides detailed preoperative diagnostic testing (TEWL-metry, capillaroscopy, gravimetric analysis, Minor test) allows to clearly objectify the pathology and its severity.

4. The most highly specific tests, which allow to objectively assess the severity of the disease and the effectiveness of surgical treatment, for hyperhidrosis is TEWL-metry, for blushing syndrome - capillaroscopy.

5. Thorough preoperative diagnostic testing, minimization of tissue trauma, as well as the correct choice of level and volume of sympathectomy ensure the absence of postoperative complications, recurrence of the disease and excellent clinical outcome.

## Disclosure

### Conflict of interest

The authors declare no conflict of interest.

### Ethical approval

All procedures performed in studies involving human participants were in accordance with the ethical standards of the institutional and national research committee and with the 1964 Helsinki declaration and its later amendments or comparable ethical standards.

### Informed consent

The written informed consent was obtained from each patient or appropriate family member before the surgery.

### Funding

The research had no sponsor support.

## References

- Caviezel C, Schuepbach R, Grande B, Opitz I, Zalunardo M, Weder W, Hillinger S. Establishing a non-intubated thoracoscopic surgery programme for bilateral uniportal sympathectomy. *Swiss Med Wkly*. 2019 Apr 17;149:w20064. doi: 10.4414/smw.2019.20064
- Migliore M, Palazzolo M, Pennisi M, Nardini M, Borrata F. Extended uniportal bilateral sympathectomy. *J Thorac Dis*. 2018 Jan 30;4:27. doi: 10.21037/jovs.2017.09.12
- Baumgartner FJ, Bertin S, Konecny J. Superiority of thoracoscopic sympathectomy over medical management for the palmoplantar subset of severe hyperhidrosis. *Ann Vasc Surg*. 2009 Jan-Feb;23(1):1-7. doi: 10.1016/j.avsg.2008.04.014
- Weng W, Liu Y, Li J, Jiang G, Liu J, Wang J. A long-term evaluation of postoperative moist hands after R4/R4+5 sympathectomy for primary palmar hyperhidrosis. *J Thorac Dis*. 2018 Mar;10(3):1532-1537. doi: 10.21037/jtd.2018.02.07
- Cerfolio RJ, De Campos JR, Bryant AS, Connery CP, Miller DL, DeCamp MM, McKenna RJ, Krasna MJ. The Society of Thoracic Surgeons expert consensus for the surgical treatment of hyperhidrosis. *Ann Thorac Surg*. 2011 May;91(5):1642-8. doi: 10.1016/j.athoracsur.2011.01.105
- Hajjar WM, Al-Nassar SA, Al-Sharif HM, Al-Olayet DM, Al-Otiebi WS, Al-Huqayl AA, Hajjar AW. The quality of life and satisfaction rate of patients with upper limb hyperhidrosis before and after bilateral endoscopic thoracic sympathectomy. *Saudi J Anaesth*. 2019 Jan-Mar;13(1):16-22. doi: 10.4103/sja.SJA\_335\_18
- Ishy A, de Campos JR, Wolosker N, Kauffman P, Tedde ML, Chiavoni CR, Jatene FB. Objective evaluation of patients with palmar hyperhidrosis submitted to two levels of sympathectomy: T3 and T4. *Interact Cardiovasc Thorac Surg*. 2011 Apr;12(4):545-8. doi: 10.1510/icvts.2010.252015
- Hughes J. Endothoracic Sympathectomy. *Proc R Soc Med*. 1942 Jul;35(9):585-6.
- Eroshkin OA, Sokolov VV, Romanukha DM, Omelchenko AV, Voytsekhovskyy SS. [Device for monoportal video-assisted thoracoscopic sympathectomy]. Application for a patent of Ukraine u 2020 08213 dated 12/21/2020. A positive decision was received on 03/19/2021. Ukrainian.
- Basra MK, Fenech R, Gatt RM, Salek MS, Finlay AY. The Dermatology Life Quality Index 1994-2007: a comprehensive review of validation data and clinical results. *Br J Dermatol*. 2008 Nov;159(5):997-1035. doi: 10.1111/j.1365-2133.2008.08832.x
- Kowalski JW, Eadie N, Dagget S, Lai P-Y. Validity and reliability of the hyperhidrosis disease severity scale (HDSS). *Journal of the American Academy of Dermatology*. 2004 Mar;50(3):P51. dx: 10.1016/j.jaad.2003.10.202
- Tetteh HA, Groth SS, Kast T, Whitson BA, Radosevich DM, Klopp AC, D'Cunha J, Maddaus MA, Andrade RS. Primary palmoplantar hyperhidrosis and thoracoscopic sympathectomy: a new objective assessment method. *Ann Thorac Surg*. 2009 Jan;87(1):267-74; discussion 274-5. doi: 10.1016/j.athoracsur.2008.10.028
- Miotto A, Honda PAA, Bachichi TG, Holanda CS, Evangelista Neto E, Perfeito JAJ, Leão LEV, Costa ADS Jr. Comparative study of transepidermal water loss in patients with and without hyperhidrosis by closed-chamber measurer in an air-conditioned environment. *Einstein (Sao Paulo)*. 2018 Nov 8;16(4):eAO4312. doi: 10.31744/einstein\_journal/2018AO4312
- Kanda Y. Investigation of the freely available easy-to-use software 'EZ' for medical statistics. *Bone Marrow Transplant*. 2013 Mar;48(3):452-8. doi: 10.1038/bmt.2012.244
- Du X, Zhu X, Wang T, Hu X, Lin P, Teng Y, Fan C, Li J, Xi Y, Xiao J, Liu W, Zhang J, Zhou H, Tian D, Yuan S. Compensatory hyperhidrosis after different surgeries at the same sympathetic levels: a meta-analysis. *Ann Transl Med*. 2018 Jun;6(11):203. doi: 10.21037/atm.2018.05.24
- Sternbach JM, DeCamp MM. Targeting the Sympathetic Chain for Primary Hyperhidrosis: An Evidence-Based Review. *Thorac Surg Clin*. 2016 Nov;26(4):407-420. doi: 10.1016/j.thorsurg.2016.06.005
- de Paula Loureiro M, de Campos JR, Wolosker N, Kauffman P, editors. *Hyperhidrosis: A Complete Guide to Diagnosis and Management*. Springer; 2018. doi: 10.1007/978-3-319-89527-7
- Jeganathan R, Jordan S, Jones M, Grant S, Diamond O, McManus K, Graham A, McGuigan J. Bilateral thoracoscopic sympathectomy: results and long-term follow-up. *Interact Cardiovasc Thorac Surg*. 2008 Feb;7(1):67-70. doi: 10.1510/icvts.2007.162479
- Heidemann E, Licht PB. A comparative study of thoracoscopic sympathectomy versus local surgical treatment for axillary hyperhidrosis. *Ann Thorac Surg*. 2013 Jan;95(1):264-8. doi: 10.1016/j.athoracsur.2012.08.103
- Aoki H, Sakai T, Murata H, Sumikawa K. Extent of sympathectomy affects postoperative compensatory sweating and satisfaction in patients with palmar hyperhidrosis. *J Anesth*. 2014 Apr;28(2):210-3. doi: 10.1007/s00540-013-1692-7
- Cohen JL, Cohen G, Solish N, Murray CA. Diagnosis, impact, and management of focal hyperhidrosis: treatment review including botulinum toxin therapy. *Facial Plast Surg Clin North Am*. 2007 Feb;15(1):17-30, v-vi. doi: 10.1016/j.fsc.2006.10.002
- Nawrocki S. *Diagnosis and qualitative identification of hyperhidrosis*. AME Publishing Company; 2019 Jul;3:35-35. doi: 10.21037/shc.2019.06.04