

Ukr Neurosurg J. 2021;27(2):16-24  
doi: 10.25305/unj.223481

## The comparative analysis of MRI data in the early period after lumbar microdiscectomies with epidural injection of polyacrylamide hydrogel

Eugene G. Pedachenko<sup>1</sup>, Mykhaylo V. Khyzhnyak<sup>1</sup>, Olena P. Krasylenko<sup>2</sup>, Yuriy E. Pedachenko<sup>1,3</sup>, Olexandr F. Tanaseychuk<sup>1</sup>, Volodymyr A. Kramarenko<sup>1</sup>, Andriy M. Furman<sup>4</sup>, Oksana V. Zemskova<sup>5,6</sup>

<sup>1</sup> Department of Miniinvasive and Laser Neurosurgery, Romodanov Neurosurgery Institute, Kyiv, Ukraine

<sup>2</sup> Department of CNS Trauma, Romodanov Neurosurgery Institute, Kyiv, Ukraine

<sup>3</sup> Department of Neurosurgery, Shupyk National Healthcare University of Ukraine, Kyiv, Ukraine

<sup>4</sup> NeuroTrauma Department, Romodanov Neurosurgery Institute, Kyiv, Ukraine

<sup>5</sup> Radioneurosurgery Department, Romodanov Neurosurgery Institute, Kyiv, Ukraine

<sup>6</sup> Department of Adjuvant Treatment for CNS Tumors, Romodanov Neurosurgery Institute, Kyiv, Ukraine

Received: 19 January 2021

Accepted: 02 April 2021

### Address for correspondence:

Oksana V. Zemskova, Department of Radioneurosurgery, Romodanov Neurosurgery Institute, 32 Platona Maiborody st., Kyiv, 04050, Ukraine, e-mail: oxzemskova@gmail.com

**Objective:** To perform a comparative analysis of MRI data obtained in the early postoperative period after repeated lumbar microdiscectomies in patients with and without epidural injection of "Nubiplant" polyacrylamide hydrogel (HG).

**Material and methods:** The MRI data of the lumbar spine in the early postoperative period after repeated removal of herniated disc (on the 3-15th day) in 84 (100%) patients were analyzed: 30 (35,7%) patients were injected intraoperatively epidurally with "Nubiplant" HG to prevent epidural fibrosis (main group (MG) and in 54 (64,3%) patients the HG was not injected (control group (CG)).

**Results:** Comparative analysis of MRI data on the 3-15th day after surgery showed that the frequency of epidural edema and hemorrhage signs within the postoperative area in the MG was significantly lower as compared to the CG ( $p=0,0444$  and  $p=0,0288$  respectively).

To assess the accuracy of the epidural administration of an artificial biopolymer Nubiplant during lumbar microdiscectomy, in the early postoperative period the following MRI criteria could be helpful: i) absence of the dural sac deformation and dislocations of the spinal root; ii) well-defined margin of the adjacent spinal root; iii) homogeneous MRI signals of the Nubiplant zone; iv) absence of Nubiplant areas outside the postoperative area; v) sufficient sectoral coverage of the adjacent root with epidurally administered Nubiplant (optimally  $>180^\circ$ ). Nubiplant" HG in the patients of the MG was evaluated, and MRI criteria for assessing the correctness of its introduction were proposed.

**Conclusions:** In the early period after repeated lumbar microdiscectomies (on the 3-15th day), intraoperative epidural injection of "Nubiplant" HG was accompanied by a significant decrease of epidural edema and hemorrhage signs within the postoperative area. The proposed criteria of correctness of HG "Nubiplant" introduction allow unifying the approaches in radiological assessment of this patients.

**Keywords:** lumbar microdiscectomy; MRI; prevention of epidural fibrosis; hydrogel "Nubiplant"

### Introduction

"Failed back surgery syndrome (FBSS)", according to various estimates, is observed in 10-40% of patients after spinal surgery [1,2]. The development of this syndrome after microdiscectomy is associated with structural and biomechanical postoperative changes of the spine (progression of intervertebral disc degeneration (IVD) and spondylarthrosis, the development of instability of the operated spinal motion segment, etc.), as well as with iatrogenic factors, in particular with inadequate intervertebral disc degeneration hernia removal [3]. A significant proportion (about 20–36%) of FBSS cases and about a quarter of reoperations for it are caused by postoperative reactive compression cicatricial adhesive process around the dura mater and neurovascular

formations of the spinal canal [4–6]. Epidural fibrosis as the main or concomitant pathology is practically an obligatory finding in repeated operations on the spine [6–8].

Repeated surgical interventions for epidural fibrosis are associated with a high risk of complications (rupture of the dural membrane, nerve root injury, epidural bleeding) and are effective only in 30-35% of patients, and in 15-20% - lead to worsening of symptoms [7, 9,10]. Reoperations do not prevent recurrence of the cicatricial adhesive process and cause thickening of the dural membrane [7,11].

The pathogenesis of epidural fibrosis is a matter of debate. The formation of scar tissue is a physiological response to any surgical injury, but the intensity and



duration of this process depends on many factors. An important mechanism of excessive scarring is the transformation of postoperative hematoma into fibrous tissue [8,12]. A directly proportional relationship between the volume of hematoma and the severity of aseptic productive epidural inflammation has been established [13]. Chronic epidural inflammation can be maintained due to autoimmune response to the appearance of IVD elements in the spinal canal, which has antigenic properties as an extra barrier tissue [14,15]. Epidural penetration of fibroblasts from the connective tissue of paravertebral muscles along the surgical trajectory leads to an increase in collagen synthesis in this area [14]. The destruction of epidural fat and damage to the ligamentum flavum affect the aggressiveness of the epidural scarring process [16]. Some technical features of the operation contributing to its overall traumatic effects are also important [7]: the use of electrocoagulation for the purpose of intracanal hemostasis, excessive traction of the dural sac and curettage of the IVD cavity.

Considering the multifactorial pathogenesis of epidural fibrosis, various approaches have been proposed for its prevention and treatment: both conservative (non-invasive and invasive) and surgical [4,7,17–26], but the study of their effectiveness indicates the need for further search for ways to solve this problems. One of the most promising current approaches consists in the use of barrier biological materials (autologous tissues and polymers), which separate the exposed dura mater from the surrounding tissues, minimizing the frictional effect [7,22]. However, the role of modern barrier biomaterials is not limited to a purely mechanical effects as the additional leverage to restrain the development of adhesive epidural process. Thus, polymer materials are used as carriers for controlled release of chemical compounds for targeted delivery of substances that slow down the development of epidural fibrosis (steroids, nonsteroidal anti-inflammatory, immunomodulatory, anti-cancer drugs, statins, inhibitors of transforming growth factor -  $\beta$  (TGF- $\beta$ ) and other profibrotic cytokines) [7,21,27–30]. The use of a biopolymer scaffold with implanted autologous stem cells of adipose origin improves the regeneration of epidural adipose tissue [31], while autologous subcutaneous fat grafts demonstrate ambiguous results in reducing epidural adhesion [7,32,33].

There are many clinically or experimentally tested autotransplants as well as biopolymers - natural (chitosan, fibrin gel, hyaluronate, amniotic membrane, gelatin sponge, etc.) and artificial (polytetrafluoroethylene, nano-hydroxyapatite from multi - (amino acid) copolymer, poly lactic-co-glycolic acid, polyethylene glycol etc.) including those with a controlled resorption time [7,9,10,17,22,30,34–37]. However, the search for an optimal anti-adhesive barrier biomaterial continues, since none of them has demonstrated a consistently high efficiency and absolute safety [5,22]. The main disadvantages of natural biopolymers are their uneven distribution and insufficient lifetime in the site of their application. Most synthetic polymeric materials are characterized by a reactive inflammatory reaction during their integration into the tissues of the human body [30, 38]. Research is continued on biopolymers and

methods of their use to prevent postoperative epidural adhesion [22].

**Objective:** to conduct a comparative analysis of magnetic resonance imaging data obtained in the early period after repeated lumbar microdiscectomies in patients with/without intraoperative epidural injection of polyacrylamide hydrogel "Nubiplant".

## Materials and methods

### Study participants

84 patients with recurrent IVD hernia were involved in a single-center prospective cohort study. Surgical treatment and analysis of its results were carried out in the clinic of minimally invasive and laser spinal neurosurgery with the X-ray operating room of the Romodanov Neurosurgery Institute, Ukraine.

All patients gave informed and voluntary written consent to participate in the study.

The study was approved by the Committee on Ethics and Bioethics of the Romodanov Neurosurgery Institute, Ukraine (Meeting Minutes No.3 of June 6, 2016).

### Inclusion criteria:

- age of patients from 18 to 76 years;
- repeated surgery to remove IVD hernia and decompression of the spinal root;
- early postoperative period;
- functional status of the patient according to the Karnofsky scale is not less than 70 points.

### Characteristics of groups

The main group (MG) included 30 (35.7%) patients who at the final stage of the operation were epidurally injected with polyacrylamide hydrogel (HG) "Nubiplant", the control group (CG) included 54 (64.3%) patients who underwent reintervention without HG injection.

The age of patients in MG - from 24 to 63 years, in CG - from 20 to 75 years (**Table 1**).

### Study design

Patients of MG at the final stage of surgery to remove IVD hernia and decompression of the spinal root for the prevention of cicatricial-adhesive epidural fibrosis were epidurally injected with HG "Nubiplant" layer-by-layer in the amount corresponding to the volume of musculoligamentous-bone formations and adipose tissue (2.0–2.5 mm<sup>3</sup>) removed during the surgical approach. First, the anterior epidural space was filled, then the root and intralaminar space were covered. Thorough hemostasis was achieved.

Patients of CG underwent repeated surgery to remove IVD hernia and decompression of the spinal root, but without the injection of HG.

**Table 1.** Characteristics of study groups

Patients group	n	Indicator				
		average age, years	men		women	
			Abs.	%	Abs.	%
main	30	42.9±1.7	17	56.7	13	43.3
control	54	47.0±6.0	30	55.6	24	44.4
p		0.513	0.922			

MRI examination was performed on the 3–15th day after surgery on an “Intera 1.5 T1” tomograph (Philips, Netherlands) with a magnetic field induction of 1.5 T. MRI examination protocol: sagittal and axial T1w\_TSE and T2w\_TSE standard turbo spin echo, sagittal with suppression of MR signal from adipose tissue (STIR\_TSE), coronal T2w\_TSE. Postoperative MRI data of patients of the main and control groups were compared.

### Statistical analysis

Databases were formed in Excel tables. Statistical calculations were performed using specialized software Statistica 64 ver.10.0.1011.0 StatSoft Inc. For the purpose of statistical data processing, the input frequency tables were converted into contingency tables which show the frequency distribution of variables in groups taking into account the presence of low frequencies for a sign of pronounced epidural edema in the postoperative area (POA).

The null hypothesis regarding the frequency of epidural edema and hemorrhage manifestations in the groups was tested with the  $\alpha$ -level of statistical significance of 5% by Fisher’s exact test, that allows accounting for low frequencies.

### Results and discussion

Magnetic resonance imaging is a common method of objectifying postoperative changes in patients operated on for IVD hernias, both in the early postoperative period and in the long-term [39-41]. The main advantages of MRI include high resolution, which provides contrast in soft tissues imaging, the possibility of 3D imaging and the absence of radiation exposure. In patients with IVD pathology, high contrast (between foraminal or epidural fatty component and IVD or osteophyte, between the cerebrospinal fluid and the spinal cord or spinal root) in combination with multiplanar imaging allows an accurate assessment of IVD hernias and spinal stenosis, in particular during postoperative follow-up.

Despite the wide range of surgical approaches to the treatment of IVD pathology, clinical issues for MRI diagnostics in the postoperative period can be classified into several main categories, directly or indirectly related to the main causes of FBSS development [1,5,42–44]:

- IVD hernia (any *de novo*, relapse at the level of surgery, ineffective herniectomy);
- postoperative cicatricial-adhesive epidural fibrosis;
- cerebrospinal fluid cysts;
- facet degenerative changes;
- spinal stenosis (foraminal or central);
- infectious complications (from soft extravertebral tissues, epiduritis, arachnoiditis, osteomyelitis, spondylodiscitis);
- mechanical instability of the spinal motion segment, spondylolisthesis;
- inadequacy of the surgery level;
- hematoma, epidural edema, pseudomeningocele;
- varicose epidural veins;
- pathology unrecognized before the operation or acquired after surgery (traumatic, tumors of the spine and intracanal structures, etc.).

Outlined above categorization is generalized and does not take into account the period of postoperative follow-up. Therefore, it is clear that in a particular

observation, MRI data will correlate with the duration of postoperative period and reflect the specificity of the follow-up period (early, intermediate or remote).

MRI diagnostics has some clinical and technical limitations (overweight of the patient, claustrophobia, tremor, the presence of a pacemaker and metal implants (except those made of titanium and tantalum, which cause fewer artifacts than stainless steel)) [44].

There is an ongoing discussion on the advisability of using paramagnetic intravenous contrast with gadolinium compounds in MRI assessment of the results of IVD hernia removal. In our study, intravenous paramagnetic contrast was not used, since MRI was performed in the early postoperative period. Considerations about the inconsistency of the use of contrast in the early postoperative period are based on numerous publications, which indicate a high frequency of accumulation of paramagnetic by various anatomical structures at the level of discectomy and the absence of connection between such findings and clinical symptoms. It was found that during the early and intermediate postoperative period such contrast can be attributed to the “normal variant”. It should also be taken into account that, in addition to therapeutic toxicity (nephro- and hepatotoxicity) and the ability of gadolinium preparations to cause allergic reactions, MRI is one of the most expensive diagnostic procedures, especially when using intravenous paramagnetic contrast.

In the first 6 weeks after surgery for IVD hernias 67% of patients show the accumulation of paramagnetic in the space of the operated disc [45], which during this observation period is not attributed to pathological MRI findings. The “normal variant” in the first 6 weeks also includes accumulation of paramagnetic by the annulus fibrosus and spinal roots at the level of the operation. In 20–62% of asymptomatic patients 3–6 weeks after surgery, the accumulation of paramagnetic in spinal roots is observed due to local disturbance of the blood-root barrier [41]. Later than the 6th month, the accumulation of paramagnetic in the spinal root is considered pathological [45]. S.D. Boden et al. demonstrated that after a successful discectomy, accumulation of paramagnetic by facet joints at the surgical level was recorded in 88% of cases, accumulation of paraspinal muscles - in 100% of cases. As the duration of observation increased, the contrast intensity decreased [46].

Considering the above, it is inappropriate to use a paramagnetic during the MRI assessment of the state of POA after discectomy in the early postoperative period in the absence of special clinical requests that require contrast enhancement (for example, if an infectious or neoplastic process is suspected).

Assessment of MRI data obtained in the early postoperative period for IVD pathology is difficult and can lead to improper conclusions. The reasons for this are an increase in the volume of soft tissues of the anterior epidural space and the absence of a clear contour of annulus fibrosus due to edema, tissue integrity disruption and the presence of hemorrhage in POA [40,47,48]. In 80% of cases in the early postoperative period in POA there is epidural edema

with a mass effect, which can be incorrectly assessed as a recurrence of IVD hernia [41]. In addition to the misinterpretation of radiological data as hernia recurrence, the corresponding changes in POA during this period can be misinterpreted as the development of cicatricial-adhesive epidural fibrosis, characteristic of the late postoperative period [41,46].

The main features of the MRI assessment of the state of the POA were set up, taking into account the peculiarities of early postoperative period of lumbar microdiscectomies and the presence of HG in patients of the main group:

1. Epidural edema and increased soft tissue volume (can affect hernia recurrence).
2. Presence of hemorrhage.
3. The degree of deformation of the dural sac.
4. Shape, clear contours, localization of the spinal root, increase in its volume, compression, dislocation.
5. The size of the HG zone, the homogeneity of the signal from the HG and the degree of coverage of the spinal root (<90°, 90–180°, >180°).

Criteria for the correctness of HG injection according to MRI data in the early postoperative period have been developed:

1. No deformation of the dural sac.
2. Absence of the spinal root dislocation.
3. Clear contours of the spinal root.
4. Homogeneity of the signal from HG on T2- and T1-weighted images.
5. Nonvisualization of HG areas outside the POA.

6. Sectoral coverage of the root by epidural HG >180°.

The degree of spinal root coverage and the duration of this effect depend on both the physical characteristics of HG (adhesion, density, fluidity, homogeneity, reverse deformation, etc.) and on injection technique, in particular careful pre-mobilization of the root by radiculolysis during IVD hernia removal. According to our intraoperative and neuroimaging comparisons, full coverage is achieved precisely when the root is displaced, which allows filling the ventral zones of the epidural space. The proposed criteria for the correctness of the HG location are simple, but help to comprehensively assess the specifics of changes after surgery. This makes it possible to unify approaches to radiological assessment of the corresponding category of patients.




The data on the degree of spinal root coverage with hydrogel in the main group are given in **Table 2**.

The presence and severity of certain parameters of the location of HG “Nubiplant” in the studied patients were also assessed (**Table 3**).

Tomograms of patients obtained in the early postoperative period after repeated removal of IVD hernias are shown in **Fig. 1** (while injecting HG “Nubiplant”) and **Fig. 2** (without the injection of HG).

Considering that epidural edema and hemorrhage in the early postoperative period are associated with the development of cicatricial adhesive epidural fibrosis in the later follow-up period [41,46], a comparative analysis

**Table 2.** Distribution of patients by the degree of spinal root coverage with epidural hydrogel «Nubiplant» (according to MRI data)

Sectoral coverage of the spinal root					
<90°		90-180°		>180°	
					
Abs.	%	Abs.	%	Abs.	%
4	13.3	17	56.7	9	30.0

**Table 3.** Assessment of MRI parameters of the location of the epidural hydrogel «Nubiplant»

Parameter	Degree of severity					
	absence		moderate		severe	
	Abs.	%	Abs.	%	Abs.	%
Dural sac deformation	23	76.7	4	13.3	3	10.0
Spinal root dislocation	27	90.0	3	10.0	0	0
Indistinct contours of the spinal root	22	73.3	6	20.0	2	6.7
Heterogeneity of the signal from the hydrogel	23	76.7	6	20.0	1	3.3
Areas of hydrogel outside POA	30	100	0	0	0	0

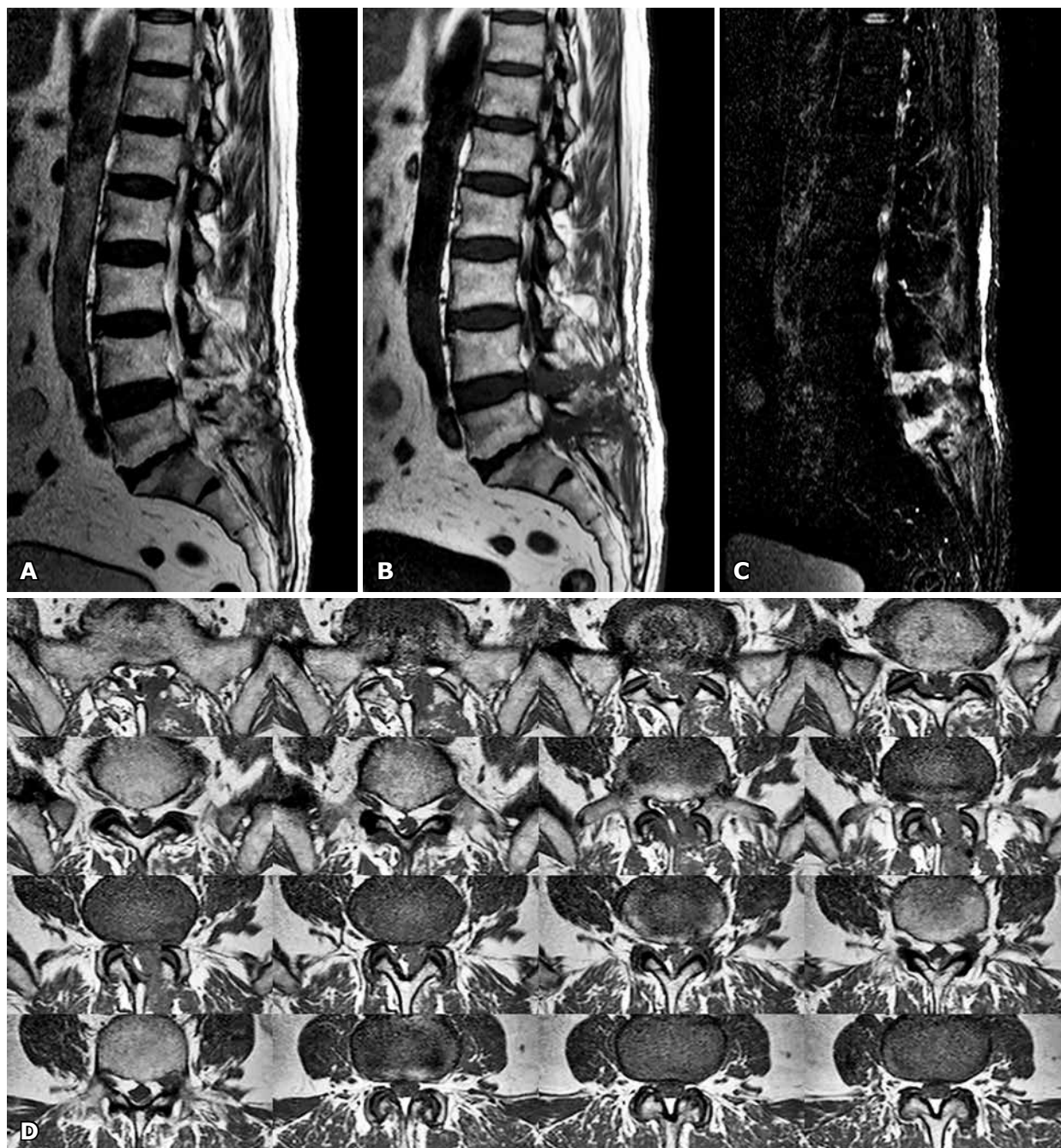
of the distribution of these signs in the study groups was carried out to assess the impact of HG administration on the possibility of creating preconditions minimizing the development of cicatricial-adhesive epidural fibrosis (**Table 4**).

Hemorrhage in POA did not cause a mass effect with the corresponding clinical symptoms and did not require repeated surgical intervention in none of the observations in MG and CG.

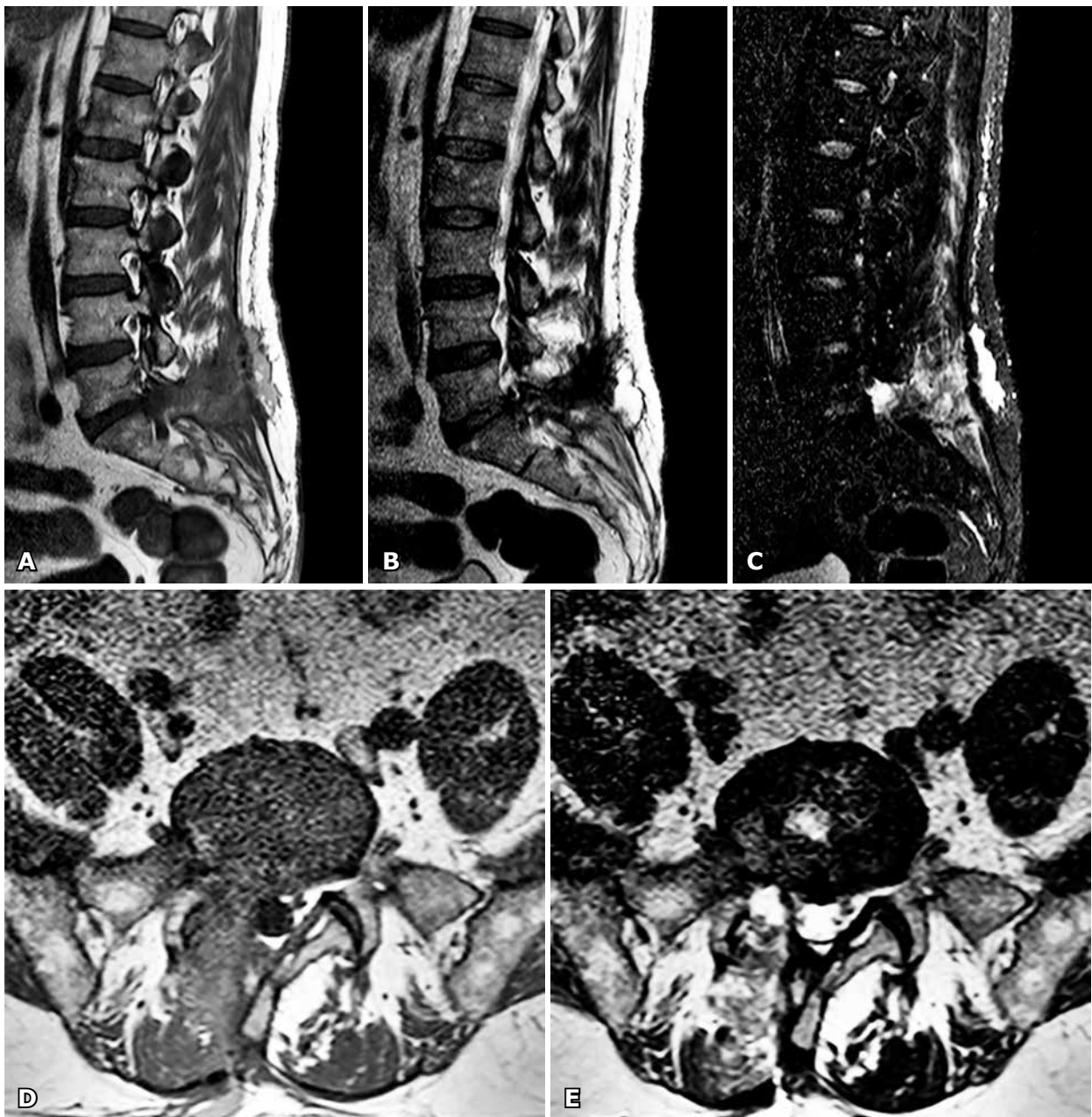
The null hypothesis of no difference in the frequency of MRI signs of epidural edema and hemorrhage

between MG and CG was rejected ( $p=0.0444$  and  $p=0.0288$ , respectively, **Table 5**), that is, the groups were statistically significantly different in MRI signs. The p-value for testing signs of epidural edema is close to the level of  $\alpha$ -value.

Thus, the use of HG "Nubiplant" for repeated microdissectomies is accompanied by a statistically significant decrease in the frequency of MRI signs of epidural edema and hemorrhage in the POA in the early postoperative period, taking into account the pathogenetic mechanisms of cicatricial adhesive epidural fibrosis.



**Fig. 1.** MRI of patient S. (early postoperative period) after repeated removal of IVD hernias L4-L5, L5-S1 on the left, elimination of epiduritis and stenosis while injecting hydrogel "Nubiplant" into the epidural space at the level of L4-L5, L5-S1: A - T2-weighted image, sagittal projection; B - T1-weighted image, sagittal projection; C - protocol with suppression of MR signal from adipose tissue (STIR\_TSE), sagittal projection; D - T2-weighted image, axial projection (multilevel images)



**Fig. 2.** MRI of the patient M. (early postoperative period) after repeated removal of IVD hernia L5-S1 on the right, removal of cicatricial adhesive changes (without hydrogel injection): A - T2-weighted image, sagittal projection; B - T1-weighted image, sagittal projection; C - protocol with suppression of MR signal from adipose tissue (STIR\_TSE), sagittal projection; D - T1-weighted image, axial projection; E - T2-weighted image, axial projection

**Table 4.** Frequency and severity of MRI signs of epidural edema and hemorrhage in the postoperative area

Group of patients	MRI signs											
	epidural edema						hemorrhages					
	absent		moderate		severe		absent		moderate		severe	
	Abs.	%	Abs.	%	Abs.	%	Abs.	%	Abs.	%	Abs.	%
Main (n=30)	23	76.7	6	20.0	1	3.3	25	83.3	5	16.7	0	0
Control (n=54)	30	55.6	15	27.8	9	16.7	33	61.1	21	38.9	0	0

**Table 5.** Results of calculating the frequencies of MRI signs of epidural edema and hemorrhage in the postoperative area (Fisher's exact test)

Indicator	MRI signs					
	epidural edema			hemorrhages		
	absent	present	total	absent	present	total
Main group (n=30)	23	7	30	25	5	30
Percent of total	27.4	8.3	35.7	29.8	5.9	35.7
Control group (n=54)	30	24	54	33	21	54
Percent of total	35.7	28.6	64.3	39.3	25.0	64.3
Overall population	53	31	84	58	26	84
Percent of total	63.1	36.9	100	69.0	31.0	100.0
Fisher exact p	p=0.0444			p=0.0288		

A promising line of research is a comparative analysis of MRI data in patients with recurrent IVD hernias, who were injected with HG "Nubiplant" for lumbar microdiscectomy, and those who did not use it, in later periods of observation. In our opinion, such findings will allow us to study the predictive effect of the use of this anti-adhesive barrier biomaterial on the development of postoperative epidural fibrosis and FBSS. In addition, it is advisable to conduct a multivariate analysis of the influence of various clinical factors (in particular body mass index, degree of sarcopenia, comorbidity, degenerative-dystrophic changes of the spine, etc.) on the results of repeated microdiscectomies using HG "Nubiplant". Such studies, provided that the sample size is increased to enhance the statistical significance of obtained results, would contribute to the development of treatment algorithms with a high degree of evidence and individualization of approaches to the choice of optimal surgical approach while ensuring a high quality of life in the postoperative period. Thus, our study indicates the need for further comprehensive analysis of the results of lumbar microdiscectomies when using HG "Nubiplant" in later follow-up periods.

### Conclusions

1. It was found that in the early period after repeated lumbar microdiscectomies (on the 3–15th day) intraoperative epidural injection of "Nubiplant" hydrogel is accompanied by a statistically significant decrease in the frequency of MRI signs of epidural edema and hemorrhage in the postoperative area ( $p=0,0444$  and  $p=0,0288$ , respectively).

2. When assessing the correctness of epidural injection of "Nubiplant" hydrogel during lumbar microdiscectomies in the early postoperative period, it is advisable to use the following MRI criteria: no deformation of the dural sac and dislocation of the spinal root, clear contours of the spinal root, uniformity of the signal from the hydrogel on T-2 and T-1 weighed images, nonvisualization of hydrogel areas outside the postoperative area, sufficient sectoral coverage of the root with the hydrogel (optimally  $>180^\circ$ ).

### Disclosure

#### Conflict of interest

The authors declare no conflict of interest.

#### Ethical approval

All procedures performed in studies involving human participants were in accordance with the ethical standards of the institutional and national research committee and with the 1964 Helsinki declaration and its later amendments or comparable ethical standards.

#### Informed consent

The informed voluntary written consent to participate in the study was obtained from each patient.

#### Funding

The research had no sponsor support.

### References

- Sebaaly A, Lahoud MJ, Rizkallah M, Kreichati G, Kharrat K. Etiology, Evaluation, and Treatment of Failed Back Surgery Syndrome. *Asian Spine J.* 2018 Jun;12(3):574-585. doi: 10.4184/asj.2018.12.3.574
- Rodrigues FF, Dozza DC, de Oliveira CR, de Castro RG. Failed back surgery syndrome: casuistic and etiology. *Arq Neuropsiquiatr.* 2006 Sep;64(3B):757-61. doi: 10.1590/s0004-282x2006000500011
- Thomson S. Failed back surgery syndrome - definition, epidemiology and demographics. *Br J Pain.* 2013 Feb;7(1):56-9. doi: 10.1177/2049463713479096
- Hayek SM, Helm S, Benyamin RM, Singh V, Bryce DA, Smith HS. Effectiveness of spinal endoscopic adhesiolysis in post lumbar surgery syndrome: a systematic review. *Pain Physician.* 2009 Mar-Apr;12(2):419-35. doi: 10.36076/ppj.2009/12/419
- Rönnberg K, Lind B, Zoega B, Gadeholt-Göthlin G, Halldin K, Gellerstedt M, Brisby H. Peridural scar and its relation to clinical outcome: a randomised study on surgically treated lumbar disc herniation patients. *Eur Spine J.* 2008 Dec;17(12):1714-20. doi: 10.1007/s00586-008-0805-8
- Boscher HA, Heavner JE. Incidence and severity of epidural fibrosis after back surgery: an endoscopic study. *Pain Pract.* 2010 Jan-Feb;10(1):18-24. doi: 10.1111/j.1533-2500.2009.00311.x
- Zhivotenko AP, Koshkareva ZV, Sorokovikov VA. Prevention of postoperative epidural fibrosis: current status of the issue. *Hirurgiâ pozvonočnika (Spine Surgery).* 2019 Sep 22;16(3):74-81. doi: 10.14531/ss2019.3.74-81
- Zhivotenko AP, Sorokovikov VA, Koshkaryova ZV, Negreyeva



- MB, Potapov VE, Gorbunov AV. Modern ideas about epidural fibrosis (literature review). *Acta Biomedica Scientifica*. 2017 Nov 28;2(6):27-33. Russian. doi: 10.12737/article\_5a0a7f9e412601.50968513
9. Kanamori M, Kawaguchi Y, Ohmori K, Kimura T, Tsuji H, Matsui H. The fate of autogenous free-fat grafts after posterior lumbar surgery: part 2. Magnetic resonance imaging and histologic studies in repeated surgery cases. *Spine (Phila Pa 1976)*. 2001 Oct 15;26(20):2264-70. doi: 10.1097/00007632-200110150-00019
  10. Alkalay RN, Kim DH, Urry DW, Xu J, Parker TM, Glazer PA. Prevention of postlaminectomy epidural fibrosis using bioelastic materials. *Spine (Phila Pa 1976)*. 2003 Aug 1;28(15):1659-65. doi: 10.1097/01.BRS.0000083161.67605.40
  11. Quan M, Hwang WH, Kim JH, Kim YY. Analysis of pain markers and epidural fibrosis caused by repeated spinal surgery in Sprague-Dawley rats. *BMC Musculoskelet Disord*. 2021 Jan 5;22(1):16. doi: 10.1186/s12891-020-03920-z
  12. Gasiński P, Radek M, Józwiak J, Łyczak P. Blizna oponowa w operacjach odcinka lędźwiowego kregosłupa--mechanizm powstawania, problemy kliniczne i próby profilaktyki [Peridural fibrosis in lumbar disc surgery-pathogenesis, clinical problems and prophylactic attempts]. *Neurol Neurochir Pol*. 2000 Sep-Oct;34(5):983-93. Polish.
  13. Fadda A, Oevermann A, Vandeveld M, Doherr MG, Forterre F, Henke D. Clinical and pathological analysis of epidural inflammation in intervertebral disk extrusion in dogs. *J Vet Intern Med*. 2013 Jul-Aug;27(4):924-34. doi: 10.1111/jvim.12095
  14. Larionov SN, Sorokovikov VA, Erdyneyev KC, Lepekhova SA, Goldberg OA. Experimental Model of Intervertebral Disk Mediated Postoperative Epidural Fibrosis. *Ann Neurosci*. 2016 Jul;23(2):76-80. doi: 10.1159/000443564
  15. Erdyneev KTs, Larionov SN, Lepekhova SA, Goldberg OA, Sorokovikov VA, Sharova TV. [Evaluation of neurological disorders in experimental model of prevention postoperative epidural fibrosis]. *Vestnik Burâtskogo gosudarstvennogo universiteta. Medicina i farmaciâ*. 2013;(12):89-94. Russian.
  16. Aydin Y, Ziyal IM, Duman H, Türkmen CS, Başak M, Sahin Y. Clinical and radiological results of lumbar microdiscectomy technique with preserving of ligamentum flavum comparing to the standard microdiscectomy technique. *Surg Neurol*. 2002 Jan;57(1):5-13; discussion 13-4. doi: 10.1016/s0090-3019(01)00677-2
  17. Liu KC, Hsieh MH, Yang CC, Chang WL, Huang YH. Full endoscopic interlaminar discectomy (FEID) for recurrent lumbar disc herniation: surgical technique, clinical outcome, and prognostic factors. *J Spine Surg*. 2020 Jun;6(2):483-494. doi: 10.21037/jss-19-370
  18. Choi GJ, Park HK, Kim DS, Lee D, Kang H. Effect of statins on experimental postoperative adhesion: a systematic review and meta-analysis. *Sci Rep*. 2018 Oct 3;8(1):14754. doi: 10.1038/s41598-018-33145-z
  19. Kelten B, Erdogan H, Antar V, Sanel S, Tuncdemir M, Kutnu M, Karaoglan A, Orki T. Pentoxifylline Inhibits Epidural Fibrosis in Post-Laminectomy Rats. *Med Sci Monit*. 2016 Mar 14;22:840-7. doi: 10.12659/msm.897668
  20. Guler S, Akcali O, Sen B, Micili SC, Sanli NK, Cankaya D. Effect of platelet-rich plasma, fat pad and dural matrix in preventing epidural fibrosis. *Acta Ortop Bras*. 2020 Jan-Feb;28(1):31-35. doi: 10.1590/1413-785220202801218823
  21. Ozturk Y, Bozkurt I, Yaman ME, Guvenc Y, Tolunay T, Bayram P, Hayirli N, Billur D, Erbay FK, Senturk S, Bozkurt G. Histopathologic Analysis of Tamoxifen on Epidural Fibrosis. *World Neurosurg*. 2018 Mar;111:e941-e948. doi: 10.1016/j.wneu.2018.01.004
  22. Wang H, Sun W, Fu D, Shen Y, Chen YY, Wang LL. Update on biomaterials for prevention of epidural adhesion after lumbar laminectomy. *J Orthop Translat*. 2018 Mar 7;13:41-49. doi: 10.1016/j.jot.2018.02.001
  23. Geudeke MW, Krediet AC, Bilecen S, Huygen FJPM, Rijdsdijk M. Effectiveness of Epiduroscopy for Patients with Failed Back Surgery Syndrome: A Systematic Review and Meta-analysis. *Pain Pract*. 2020 Dec 4. doi: 10.1111/papr.12974
  24. Rapčan R, Kočan L, Mláka J, Burianek M, Kočanová H, Rapčanová S, Hess M, Hammond A, Griger M, Venglarčík M, Gajdoš M, Vašková J. A Randomized, Multicenter, Double-Blind, Parallel Pilot Study Assessing the Effect of Mechanical Adhesiolysis vs Adhesiolysis with Corticosteroid and Hyaluronidase Administration into the Epidural Space During Epiduroscopy. *Pain Med*. 2018 Jul 1;19(7):1436-1444. doi: 10.1093/pm/pnx328
  25. Albiñana-Cunningham JN, Ripalda-Cemboráin P, Labiano T, Echeveste JI, Granero-Moltó F, Alfonso-Olmos M. Mechanical barriers and transforming growth factor beta inhibitor on epidural fibrosis in a rabbit laminectomy model. *J Orthop Surg Res*. 2018 Apr 5;13(1):72. doi: 10.1186/s13018-018-0781-6
  26. de Divitiis E, Cappabianca P. Preserving the ligamentum flavum in lumbar discectomy: a new technique that prevents scar tissue formation in the first 6 months postsurgery. *Neurosurgery*. 2007 Dec;61(6):E1340. doi: 10.1227/01.neu.0000306128.54281.7d
  27. Sun Y, Yan LQ, Liang Y, Li XL, Cao XJ, Lu C. Reduction of epidural scar adhesion by topical application of simvastatin after laminectomy in rats. *Eur Rev Med Pharmacol Sci*. 2015 Jan;19(1):3-8
  28. Wang BB, Xie H, Wu T, Xie N, Wu J, Gu Y, Tang F, Liu J. Controlled-release mitomycin C-poly(lactic acid) film prevents epidural scar hyperplasia after laminectomy by inducing fibroblast autophagy and regulating the expression of miRNAs. *Eur Rev Med Pharmacol Sci*. 2017 May;21(10):2526-2537
  29. Yao H, Cao Z, Peng L, Liu J, Zhang X, Deng Z. A novel controlled release tetrandrine-loaded PDLLA film: evaluation of drug release and anti-adhesion effects in vitro and in vivo. *Drug Deliv Transl Res*. 2020 Feb;10(1):13-22. doi: 10.1007/s13346-019-00654-x
  30. Liu S, Pan G, Liu G, Neves JD, Song S, Chen S, Cheng B, Sun Z, Sarmiento B, Cui W, Fan C. Electrospun fibrous membranes featuring sustained release of ibuprofen reduce adhesion and improve neurological function following lumbar laminectomy. *J Control Release*. 2017 Oct 28;264:1-13. doi: 10.1016/j.jconrel.2017.08.011
  31. Xu J, Chen Y, Yue Y, Sun J, Cui L. Reconstruction of epidural fat with engineered adipose tissue from adipose derived stem cells and PLGA in the rabbit dorsal laminectomy model. *Biomaterials*. 2012 Oct;33(29):6965-73. doi: 10.1016/j.biomaterials.2012.06.010
  32. Görgülü A, Simşek O, Cobanoğlu S, Imer M, Parsak T. The effect of epidural free fat graft on the outcome of lumbar disc surgery. *Neurosurg Rev*. 2004 Jul;27(3):181-4. doi: 10.1007/s10143-003-0310-9
  33. Gambardella G, Gervasio O, Zaccone C, Puglisi E. Prevention of recurrent radicular pain after lumbar disc surgery: a prospective study. *Acta Neurochir Suppl*. 2005;92:151-4. doi: 10.1007/3-211-27458-8\_33
  34. Dobran M, Brancorsini D, Costanza MD, Liverotti V, Mancini F, Nasi D, Iacoangeli M, Scerrati M. Epidural scarring after lumbar disc surgery: Equivalent scarring with/without free autologous fat grafts. *Surg Neurol Int*. 2017 Aug 1;8:169. doi: 10.4103/sni.sni\_142\_17
  35. Shin SJ, Lee JH, So J, Min K. Anti-adhesive effect of poloxamer-based thermo-sensitive sol-gel in rabbit laminectomy model. *J Mater Sci Mater Med*. 2016 Nov;27(11):162. doi: 10.1007/s10856-016-5773-7
  36. Rajiv S, Drilling A, Bassiouni A, Harding M, James C, Robinson S, Moratti S, Wormald PJ. Chitosan Dextran gel as an anti adhesion agent in a postlaminectomy spinal sheep model. *J Clin Neurosci*. 2017 Jun;40:153-156. doi: 10.1016/j.jocn.2017.02.010
  37. Choi HJ, Kim KB, Kwon YM. Effect of amniotic membrane to reduce postlaminectomy epidural adhesion on a rat model. *J Korean Neurosurg Soc*. 2011 Jun;49(6):323-8. doi: 10.3340/jkns.2011.49.6.323
  38. Keskin F, Esen H. Comparison of the effects of an adhesion barrier and chitin on experimental epidural fibrosis. *Turk Neurosurg*. 2010 Oct;20(4):457-63. doi: 10.5137/1019-5149.JTN.3205-10.2



39. Papanastasiou EI, Theodorou DJ, Theodorou SJ, Pakos EE, Ploumis A, Korompilias AV, Gelalis ID. Association between MRI findings and clinical outcomes in a period of 5 years after lumbar spine microdiscectomy. *Eur J Orthop Surg Traumatol.* 2020 Apr;30(3):441-446. doi: 10.1007/s00590-019-02588-z
40. Bellini M, Ferrara M, Grazzini I, Cerase A. Neuroimaging of the Postoperative Spine. *Magn Reson Imaging Clin N Am.* 2016 Aug;24(3):601-20. doi: 10.1016/j.mric.2016.04.006
41. Babar S, Saifuddin A. MRI of the post-discectomy lumbar spine. *Clin Radiol.* 2002 Nov;57(11):969-81. doi: 10.1053/crad.2002.1071
42. Dhagat PK, Jain M, Singh SN, Arora S, Leelakanth K. Failed Back Surgery Syndrome: Evaluation with Magnetic Resonance Imaging. *J Clin Diagn Res.* 2017 May;11(5):TC06-TC09. doi: 10.7860/JCDR/2017/24930.9817
43. Yousem DM, Grossman RI. *Neuroradiology The Requisites.* 3rd ed. Mosby Inc Elsevier; 2010.
44. Ross JS. Magnetic resonance imaging of the postoperative spine. *Semin Musculoskelet Radiol.* 2000;4(3):281-91. doi: 10.1055/s-2000-9339
45. van de Kelft EJ, van Goethem JW, de La Porte C, Verlooy JS. Early postoperative gadolinium-DTPA-enhanced MR imaging after successful lumbar discectomy. *Br J Neurosurg.* 1996 Feb;10(1):41-9.
46. Boden SD, Davis DO, Dina TS, Parker CP, O'Malley S, Sunner JL, Wiesel SW. Contrast-enhanced MR imaging performed after successful lumbar disk surgery: prospective study. *Radiology.* 1992 Jan;182(1):59-64. doi: 10.1148/radiology.182.1.1727310
47. Herrera Herrera I, Moreno de la Presa R, González Gutiérrez R, Bárcena Ruiz E, García Benassi JM. Evaluation of the postoperative lumbar spine. *Radiologia.* 2013 Jan-Feb;55(1):12-23. English, Spanish. doi: 10.1016/j.rx.2011.12.004
48. Eisenmenger L, Clark AJ, Shah VN. Postoperative Spine: What the Surgeon Wants to Know. *Radiol Clin North Am.* 2019 Mar;57(2):415-438. doi: 10.1016/j.rcl.2018.10.003