

Ukr Neurosurg J. 2021;27(1):51-56
doi: 10.25305/unj.215544

Treatment strategy for the tumor cyst of the medulla in an eloquent area: a case report and review of the literature

Volodymyr O. Fedirko¹, Andrii G. Naboichenko¹, Mykola V. Iehorov¹, Albina I. Tretiakova², Oleksandra Y. Malysheva³

¹ Department of Subtentorial Neurooncology, Romodanov Neurosurgery Institute, Kyiv, Ukraine

² Functional Diagnostics Department, Romodanov Neurosurgery Institute, Kyiv, Ukraine

³ Group of Otoneurology, Romodanov Neurosurgery Institute, Kyiv, Ukraine

Received: 09 November 2020

Revised: 21 January 2021

Accepted: 29 January 2021

Address for correspondence:

Volodymyr O. Fedirko, Department of Subtentorial Neurooncology, Romodanov Neurosurgery Institute, 32 Platona Maiborody st., Kyiv, 04050, Ukraine, e-mail: fedirkovol@gmail.com

Surgical treatment of intramedullary cystic neoplasms is a challenging problem.

This is a clinical case of a 24-year-old woman with the unrescetable cystic tumor of the medulla because of eloquent area involved and severe neurological symptoms caused by the recurrent cystic component. The patient underwent emptying the cyst twice previously by means of safe entry zone myelotomy. Later there was a recurrence of the cyst with a significant neurological and overall deterioration which is typical for such neoplasms.

Recurrent cystic mass-effect was resolved with the help of newly designed device implanted. It provided simultaneous stable cisternal drainage and an opportunity for active aspiration via Ommaya reservoir.

Key words: medulla; Ommaya Reservoir; brain stem; tumor cyst; eloquent area

Among the cystic and solid tumors of the brain stem, glial tumors, hemangioblastomas are the most common, less frequent — medial gliomas of the hypothalamus with the H3 K27M mutation, cystic and solid teratomas of the medulla and intraparenchymal papillary cystic and solid meningiomas [1,2].

Regardless of the histology of the tumor, the problem is a cystic component that cannot be removed, its recurrence over time, the healing of the cyst wall fenestration and dysfunction of the drainage tube.

When it is impossible to remove a solid part of the tumor in case of cystic glial tumors of the brainstem, and only the cystic part is emptied, the cysts recur to the previous size overtime. The onset of relapse is observed in average after 2-3 months. To prevent this, various techniques are performed, in particular the use of drainage into the cyst cavity [4,5]. In some cases, even with the use of drainage, relapses occur repeatedly [6]. For patients with frequent recurrences Ommaya reservoir is inserted [8]. To determine an accurate histological diagnosis and emptying the cystic component, stereotactic surgery with minimal damage to an eloquent area is performed [7].

R. Bartoš et al. (2020) [9] performed a combined treatment of a patient with cystic mass of the medulla and a small intramural component located anteriolaterally on the left in the medulla. The first stage was the implantation of cysto-cisternal drainage, the second stage was radiosurgery with Gamma knife.

Not in all cystic tumors, the cystic component is aspirated without recurrence. There are few data

of long-term follow-up of such patients. There are discrete reports of cysto-cisternostomy [10], as well as cystoventricular shunting and endoscopic fenestration of the cyst wall between the ventricle and the cyst. The location of the catheter tip in the center of the cyst plays an important role in the stable emptying of the cyst [11].

In the series of four patients with cystic low-grade gliomas, such tumors were found to respond well to chemotherapy with bevacizumab. In all those patients there was a decrease in the cystic component. In a patient with a cystic component in the pons there was a decrease of cystic component from 2.4 × 2.4 cm to 1.4 × 1.3 cm after the treatment with bevacizumab at a dose of 10 mg per kg of body weight every two weeks for 18 months [12].

The choice of treatment strategy (tumor monitoring, microsurgical treatment or radiosurgery) for patients with cystic hemangioblastomas of the brain stem is a topical and open issue [3].

Clinical case

The 24-year-old patient gave written consent to the publication of the results of the examination, intraoperative photos and the course of treatment.

The patient complained of headache, nausea, vomiting, severe swaying while walking, dysphagia, change of voice (nasal speech), numbness of the left extremities. The history of the disease is about 10 years, when these complaints appeared. In 2010 an aspiration of the cyst and partial removal of a solid component of the tumor was performed in the Pediatric Neurosurgery Department of the Romodanov Neurosurgery Institute.



Histological examination is uninformative. After the operation, the patient's condition improved: nausea, vomiting, gait unsteadiness, numbness in left extremities and to a lesser degree dysphagia resolved. There was a slight nasal speech. Since 2018, there has been a gradual insignificant reversion of complaints. In March 2020, the condition significantly deteriorated and the patient went to the Institute of Neurosurgery with complaints that developed again and worsened in the last few weeks (gait disturbance, dysphagia, dysphonia / dysarthria, headache, constipation up to 7 days). Brain contrast enhanced Magnetic resonance imaging (MRI) (14.12.2020) revealed a tumor of the lower parts of the medulla with a cyst size $30 \times 18 \times 17$ mm and a solid component located ventrolaterally (olivary projection), the size $20 \times 10 \times 10$ mm.

Examination revealed gross static and coordination disorders of mixed origin (movement using a wheelchair, low-amplitude horizontal nystagmus, gross dysphonia and dysphagia, diffuse hypomyotonia, brisk deep reflexes, dysarthria). Symptoms have developed rapidly over the past few days.

Ophthalmological evaluation (17.03.2020): OD – 1,0, OS – 1,0. Horizontal middle-amplitude nystagmus to the right. Visual fields are not changed. Optic nerves' discs are pink, with clear boundaries. Congested retinal veins. Retinal angiopathy of both eyes.

Otolaryngological examination (17.03.2020): paresis of the soft palate. Sensitivity on the face is preserved, House Brackmann - I. Audiometry (AD = AS) - within

normal limits. Gross static and coordination disorders. Spontaneous horizontal nystagmus – middle-amplitude to the right. ENT pathology was not revealed.

Brain contrast enhanced MRI (after surgery 20.09.2010) (**Fig. 1**): on the T1-weighted images a ring-enhancing lesion is evident in the projection of the left half of the medulla and the pons with a diameter of up to 1,8 cm.

Brain contrast enhanced MRI 18.03.2020 (**Fig. 2**) revealed signs of cyst progression.

Tractography data (18.03.2020) (**Fig. 3**): cortico-spinal tracts are involved into the tumor.

Taking into account the involvement of the right and left cortico-spinal tracts into the solid part of the tumor, its removal was abandoned. The purpose of the operation was to empty the cystic cavity to eliminate compression of the brain stem structures.

Surgery was performed (March 19, 2020) - evacuation of cystic fluid in the medulla. With the help of intraoperative neurophysiological monitoring (IOM) a safe entry zone was determined (positive motor response from XI cranial nerve at 0,06 mA of monostimulation), which anatomically corresponds to the place of theoretical location (under conditions of altered anatomy) of posterolateral and postero-olivary safe entry zone (SEZ). An encephalotomy up to 5 mm longitudinally was performed by blunt dissection in the avascular space. At a depth of 5-6 mm, the cystic cavity was opened, up to 5 ml of yellowish fluid which coagulated in vitro

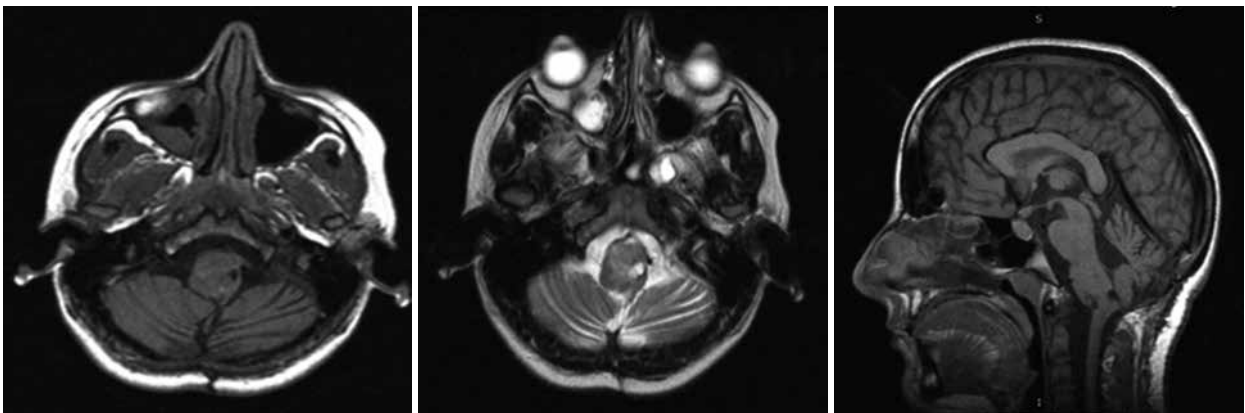


Fig. 1. MRI of the brain after surgery (2012)

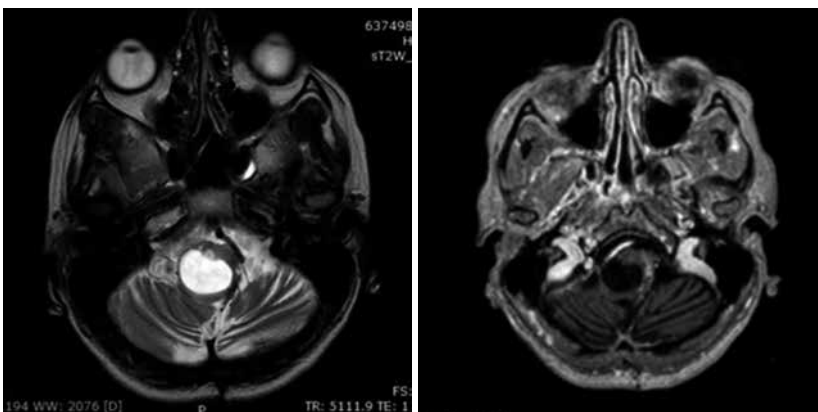


Fig. 2. MRI of the brain before surgery (18.03.2020): signs of cyst growth with its size $2.24 \times 2.38 \times 0.72$ cm. One part of a solid component is sized $0.68 \times 0.57 \times 0.76$ cm, located along the anterior cyst wall and enhanced, the other part $0.7 \times 1.1 \times 1.02$ cm in size is located to the left of the cyst and descends down to C2, inhomogeneously and intensively enhanced

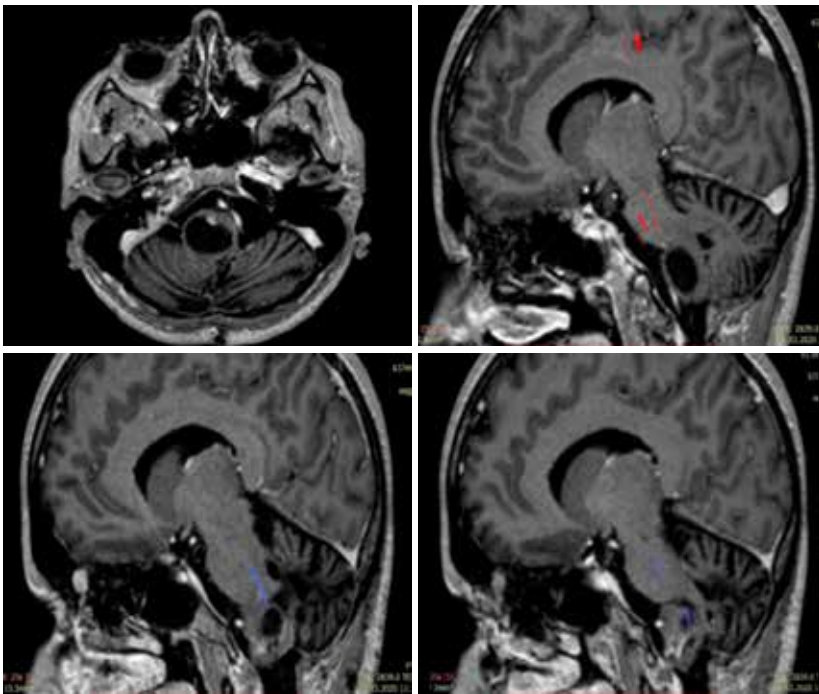


Fig. 3. MRI-tractography of the cortico-spinal tract (18.03.2020): the right (marked in red) cortico-spinal tract begins with a wide bundle from the cortex medially closer to the midline, visualized to the level of the tumor, where it breaks off; the left cortico-spinal tract (marked in dark purple) starts laterally from the cortex (postcentral gyrus), becomes thinner at the tumor level, is visualized along the cyst contour on the left and is lost in the solid part of the component located to the left of the cyst

was evacuated. In revision of the walls of the cavity a visually pathological tissue node with a diameter of several millimeters was found at the bottom. Biopsy was abandoned due to the high risk of critical hemorrhage in conditions of limited space for manipulations and prognostically unfavorable changes when stimulated with a bipolar electrode 0,01 mA - the high motor response of X cranial nerve. Macroscopically, the configuration of the medulla approached to normal, the prolapse disappeared. There were no changes observed in somatosensory evoked potentials (SSEP) and motor evoked potentials (MEP) during all manipulations.

In the early postoperative period, a significant improvement was observed in the form of regression of neurological deficit: dysphonia and non clinically significant dysphagia remained, independent gait with moderate dysbalance was restored. Karnofsky Performance Status is 80%.

Control MRI data (25.03.2020) (**Fig. 4**): the cystic component decreased in size by more than 3.5 times.

In May 2020, the symptoms gradually returned. The patient was partially able to take care of herself and moved with assistance in a wheelchair.

MRI of the brain (22.05.2020) (**Fig. 5**): signs of recurrence of the cyst $2.36 \times 2.03 \times 2.15$ cm in size (nearly baseline data).

27.05.2020: Vis: OD - 1.0, OS - 1.0. Horizontal mid-amplitude nystagmus to the right. Fields of vision are not changed. The optic nerves' discs are pale pink, the boundaries are clear, venous congestion, arteriostenosis. Retinal angiopathy of both eyes.

Operated at the Romodanov Neurosurgery Institute (04.06.2020) - evacuation of cystic fluid of the medulla with endoscopic assistance, implantation of Ommaya reservoir and cysto-cisternal drainage. IOM confirmed the "silent" area aka SEZ according to the location of

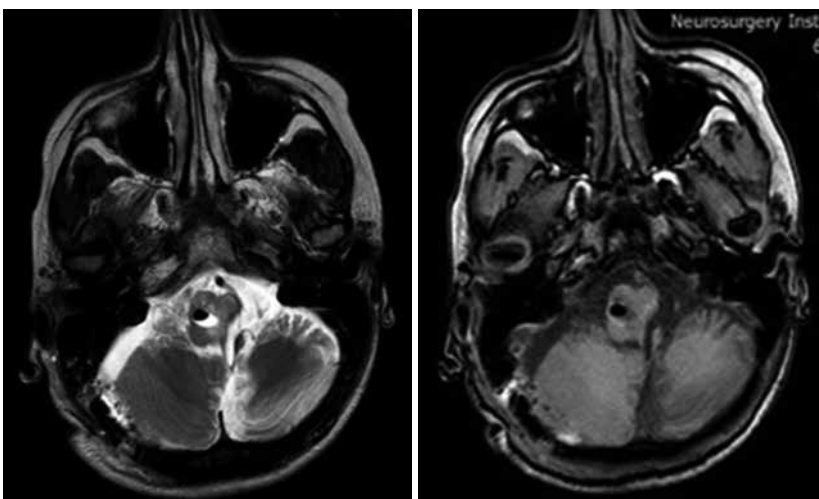


Fig. 4. MRI of the brain after surgery (25.03.2020): one part of the solid component, located along the anterior contour of the cyst $0.68 \times 0.57 \times 0.76$ cm in size (the size of the cystic component decreased by more than 3.5 times), enhances; the second part of the solid component $0.70 \times 1.10 \times 1.02$ cm in size is located to the left of the cyst and descends to C2, inhomogeneously and intensively enhances. The size of the cyst - $1.25 \times 0.36 \times 0.64$ cm

the previously performed encephalotomy, where the glial scar was visualized (**Fig. 6**).

The area anatomically corresponds to the place of the theoretical location (in conditions of altered anatomy) of the posterolateral and postero-olivary safe entry zone (SEZ). SEZ boundaries are cranially and caudally specified by monopolar stimulation at submaximal levels. Longitudinal encephalotomy up to 8 mm was performed by blunt dissection. At a depth of about 7 mm, the cystic cavity was opened, up to 5 ml of yellowish fluid was evacuated, which coagulated in vitro. In revision of the walls of the canal and cyst with an endoscope, no visually pathologically altered tissue was detected. Illumination of the endoscope provoked a temporary drop in SSEP from the left upper extremity and bradycardia to 50 beats / min. Biopsy was abandoned due to the lack of a convincing pathological

substrate, autonomous reactions, a high risk of critical hemorrhage in a limited space for manipulation and intraoperative data from the previous operation. The configuration of the medulla approached to normal, the prolapse disappeared. A duplicate of a super soft silicone drainage tube with multiple holes along the loop was inserted into the cyst cavity through the encephalotomy wound. At the top of the loop the catheter is tied to create two independent drainage directions. One end of the loop is brought out into the cisterna magna, the other — extradurally and fixed to the inner layer of the dura mater. (**Fig. 7**) Control of SSEP and MEP: correspond to the reference ones at the beginning of the operation. The Ommaya reservoir is connected to the free end of the drainage through an adapter, verified for patency and placed subgaleally in the posterotemporal area (**Fig. 8**).

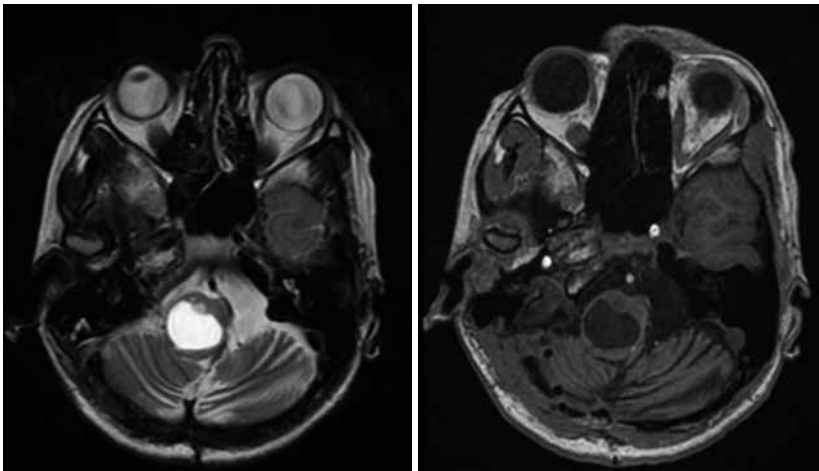


Fig. 5. MRI of the brain before surgery (22.05.2020)

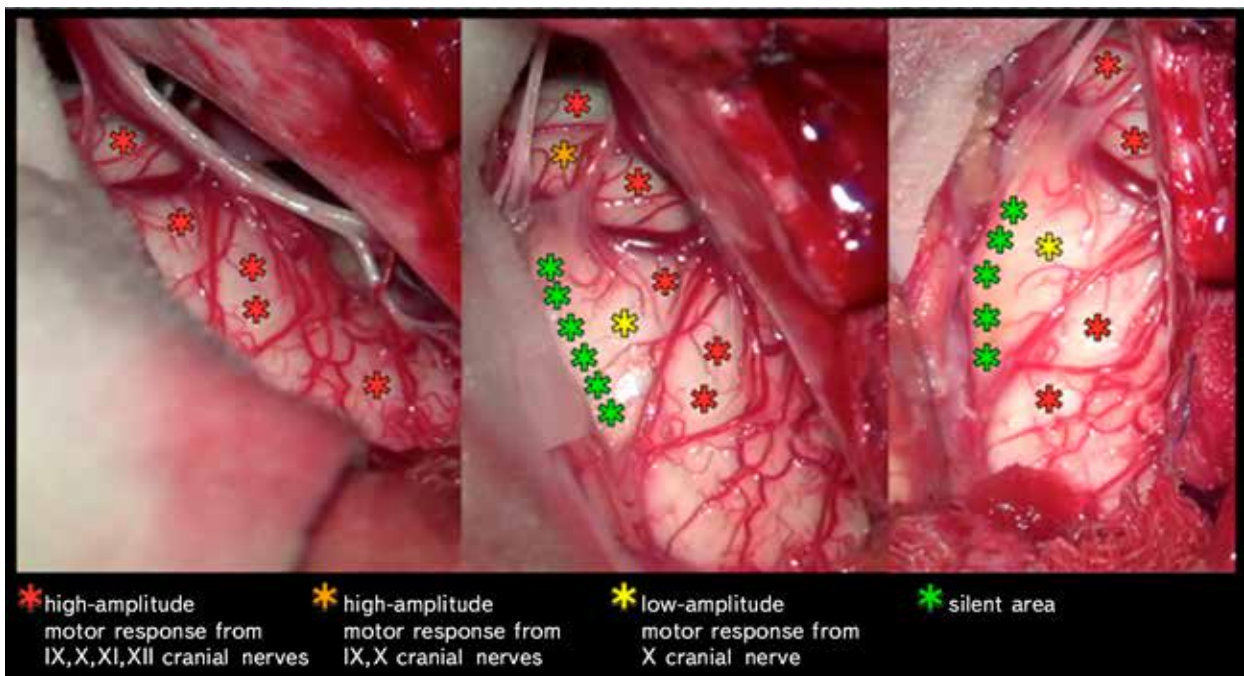


Fig. 6. Data of topical navigation of the medulla region above the tumor cyst area (photo of intraoperative monitoring)

At the time of discharge, a significant improvement was observed in the regression of neurologic deficit. The patient moves independently. Karnofsky Performance Status is 80%. Dysphonia and clinically insignificant dysphagia remained. According to the control MRI after 2 (Fig. 9) and 6 months there were no signs of continued tumor growth. The position of the implants is satisfactory. There are no signs of cystic cavity filling. Last follow-up (telephone conversation) 20.01.2021 (7.5 months after surgery): the patient's condition is satisfactory, no signs of recurrence of the mass effect or new complaints were noted.

Discussion

Repeated relapses of intramedullary cysts after their emptying are associated with severe symptoms of vital functions deterioration and often require re-interventions or drainage of the cysts, but this often does not solve the problem due to drainage dysfunction. Such cases necessitate the search for alternative care options for this category of patients. The use of a combined subarachnoid and extradural drainage of intramedullary cysts using Ommaya reservoir as a single device may be the solution. A special elastic silicone catheter is inserted into the cyst with a V-shaped loop, on the latter the holes are made and the open end of the catheter is brought out subarachnoidally with fixation of only the distal end of the drainage tube. At the same time the relative mobility of the subgaleal end brought out into the Ommaya reservoir remains. This device, because of the V-shaped duplication inserted into the cyst cavity, prevents the healing of the fenestrated cyst wall, the potential risk of intramedullary compression (after the cyst wall collapses) by the tip-edge of the tube, allows the cyst fluid to drain subarachnoidally, even if the fenestrated wall heals. In case of the cyst wall fenestration closure and obstruction of the tube outflow to the subarachnoid space, the outflow of cystic fluid to the Ommaya reservoir is potentially preserved with the cyst fluid aspiration possible or the drainage system could be washed through the Ommaya reservoir.

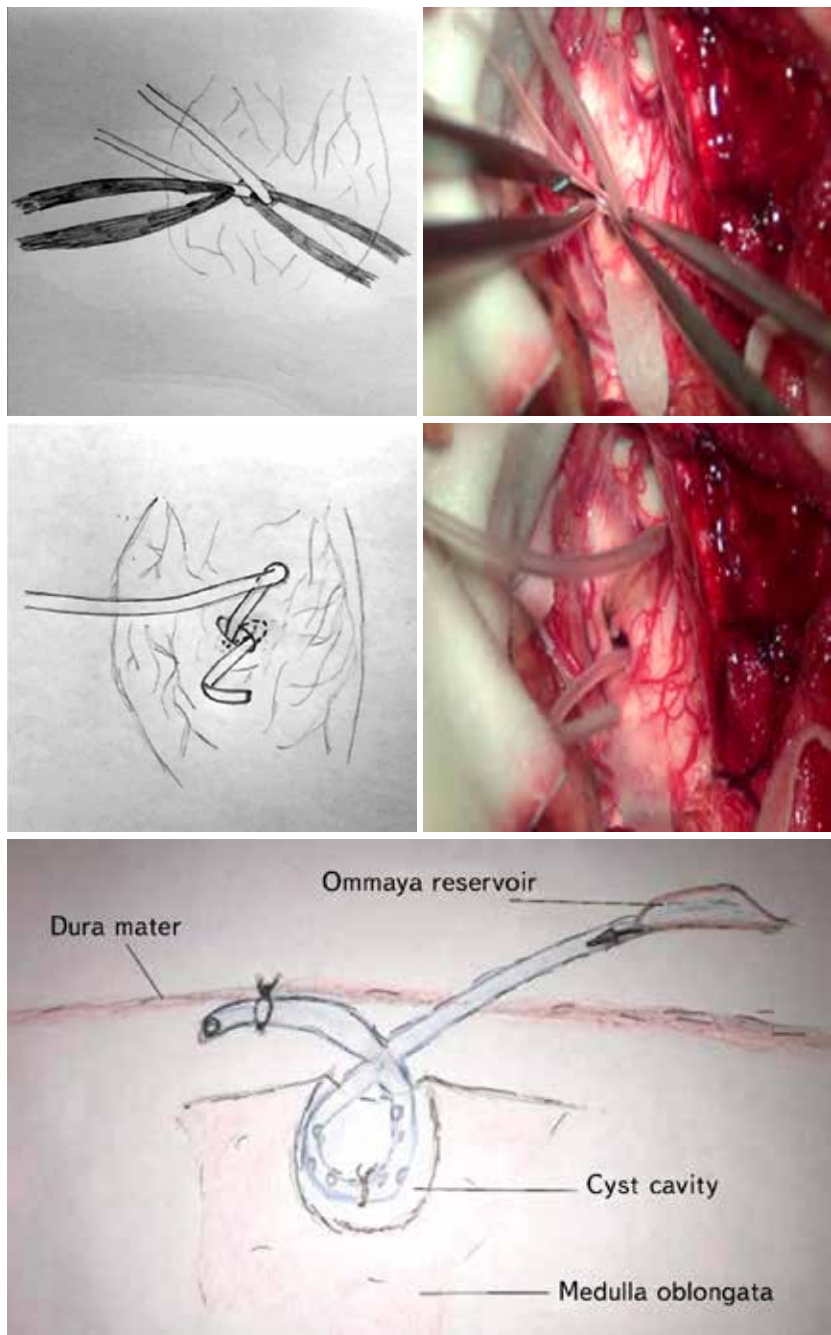


Fig. 7. Intraoperative photo and the scheme of implanted V-shaped silicone drainage in the cystic cavity

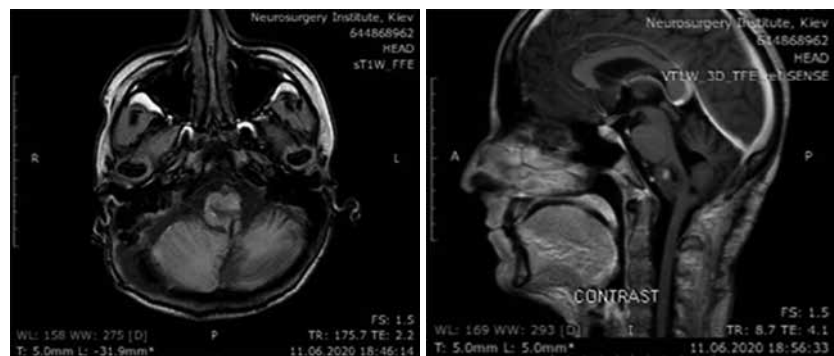


Fig. 8. MRI of the brain after surgery (11.06.2020)

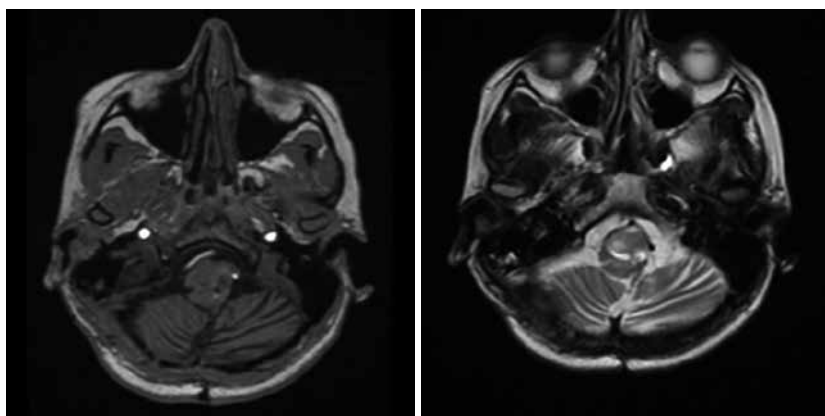


Fig. 9. MRI of the brain (28.07.2020)

Conclusions

In the treatment of tumor cysts of the brainstem, when it is impossible to remove a solid component, to prevent recurrence of the cystic component, it may be appropriate and successful to use our proposed combined subarachnoid and extradural drainage of intramedullary cysts using the Ommaya reservoir with one device. This allows you to introduce several levels of reliability to the device: 1) by tying the middle of the loop, two isolated drainage directions are created. This preserves the elastic effect of the tube on the edges of the encephalotomy wound, which prevents its sticking and maintains irrigation of the cyst cavity with cerebrospinal fluid; 2) the cysto-cisternal segment provides the possibility of drainage in case of blocking the outflow through the encephalotomy wound and when the pressure gradient increases; 3) the additional presence of the installed Ommaya reservoir through a functionally separated drainage provides the third level of control due to the possibility of active aspiration.

The combination of these technical solutions does not guarantee the success of their application, but, in our opinion, provides several levels of reliability compared to the use of unidirectional outflow.

Disclosure

Conflict of interest

The authors declare no conflict of interest.

Ethical approval

All procedures performed on the patient during the study meet the ethical standards of the Institutional and National Ethics Committees and Helsinki Declaration of 1964 and its later amendments or similar ethical standards.

Informed consent

Informed consent was obtained from the patient.

Financing

The study was performed without sponsorship.

Gratitude

We express our gratitude to T.V. Shakura for the preparation of graphic drawings.

References

- Jiang XB, Ke C, Han ZA, Lin SH, Mou YG, Luo RZ, Wu SX, Chen ZP. Intraparenchymal papillary meningioma of brainstem: case report and literature review. *World J Surg Oncol.* 2012 Jan 12;10:10. doi: 10.1186/1477-7819-10-10.
- He P, Chen W, Qiu XX, Xi YB, Guan H, Xia J. A Rare High-Grade Glioma with a Histone H3 K27M Mutation in the Hypothalamus of an Adult Patient. *World Neurosurg.* 2019 Aug;128:527-531. doi: 10.1016/j.wneu.2019.04.172.
- Xu QW, Xu R, Du ZY, Gao X. Surgical treatment for hemangioblastomas in the medulla oblongata. *Acta Neurochir (Wien).* 2010 Aug;152(8):1331-5; discussion 1335. doi: 10.1007/s00701-010-0668-8.
- Shaya MR, Fowler MR, Nanda A. Pilocytic astrocytoma presenting as an intrinsic brainstem tumor: case report and review of the literature. *J La State Med Soc.* 2004 Jan-Feb;156(1):33-6.
- Karaaslan B, Doğan E, Börcek AÖ. Management of Neonatal Facial Paralysis due to Cerebellopontine Angle Arachnoid Cyst: A Case Report. *Pediatr Neurosurg.* 2019;54(4):253-257. doi: 10.1159/000500762.
- Heran NS, Berk C, Constantoyannis C, Honey CR. Neuroepithelial cysts presenting with movement disorders: two cases. *Can J Neurol Sci.* 2003 Nov;30(4):393-6. doi: 10.1017/s0317167100003140.
- Hood TW, McKeever PE. Stereotactic management of cystic gliomas of the brain stem. *Neurosurgery.* 1989 Mar;24(3):373-8. doi: 10.1227/00006123-198903000-00011.
- Giovanini MA, Mickle JP. Long-term access to cystic brain stem lesions using the Ommaya reservoir: technical case report. *Neurosurgery.* 1996 Aug;39(2):404-7; discussion 407-8. doi: 10.1097/00006123-199608000-00039.
- Bartoš R, Lodin J, Marek T, Sameš M, Němcová V, Liščák R. Combined treatment of a medulla oblongata hemangioblastoma via permanent cysto-cisternal drainage and (postponed) gamma knife radiosurgery: a case report and review of the literature. *Int J Neurosci.* 2020 Sep 9:1-5. doi: 10.1080/00207454.2020.1819267.
- Oshima A, Kimura T, Akabane A, Kawai K. Optimal implantation of Ommaya reservoirs for cystic metastatic brain tumors preceding Gamma Knife radiosurgery. *J Clin Neurosci.* 2017 May;39:199-202. doi: 10.1016/j.jocn.2016.12.042.
- Mortini P, Bailo M, Spina A, Acerno S, Boari N, Gagliardi F. Cyst-cisternal shunting for cystic multirecurrent brainstem epidermoid: case report and literature review. *Acta Neurochir (Wien).* 2016 Jun;158(6):1197-201. doi: 10.1007/s00701-016-2813-5.
- Levenbaum E, Ellika S, Korones DN. Bevacizumab in treating the cystic components of pediatric low-grade gliomas: A report of four patients. *Pediatr Blood Cancer.* 2019 Nov;66(11):e27917. doi: 10.1002/pbc.27917.
- Sgouros S, Tsitouras V, Papaevangelou G. Endoscopic Aspiration of a Cystic Midbrain Tumour through the 4th Ventricle. *Pediatr Neurosurg.* 2016;51(5):276-8. doi: 10.1159/000445898.